

Toward a Human-Centered AI-assisted Colonoscopy System in Australia

Hsiang-Ting Chen

University of Adelaide
Adelaide, Australia
tim.chen@adelaide.edu.au

Gustavo Carneiro

University of Surrey
Surrey, United Kingdom
g.carneiro@surrey.ac.uk

Yuan Zhang

University of Adelaide
Adelaide, Australia
yuan.zhang01@adelaide.edu.au

Rajvinder Singh

Lyell McEwin Hospital
Adelaide, Australia
rajvinder.singh@sa.gov.au

ABSTRACT

While AI-assisted colonoscopy promises improved colorectal cancer screening, its success relies on effective integration into clinical practice, not just algorithmic accuracy. This paper, based on an Australian field study (observations and gastroenterologist interviews), highlights a critical disconnect: current development prioritizes machine learning model performance, overlooking essential aspects of user interface design, workflow integration, and overall user experience. Industry interactions reveal a similar emphasis on data and algorithms. To realize AI's full potential, the HCI community must champion user-centered design, ensuring these systems are usable, support endoscopist expertise, and enhance patient outcomes.

KEYWORDS

human-AI interaction, human-centred AI, colonoscopy, machine learning

ACM Reference format:

Hsiang-Ting Chen, Yuan Zhang, Gustavo Carneiro, and Rajvinder Singh. 2018. Toward a Human-Centered AI-assisted Colonoscopy System in Australia. In *Proceedings of April 2025*, Yokohama, Japan (SIGCHI '25), 6 pages.

<https://doi.org/XXXXXXX.XXXXXXX>

1 INTRODUCTION

Bowel cancer is the second most common and deadliest cancer in Australia [1]. The National Bowel Cancer Screening Program (NBCSP) recommends colonoscopy for high-risk individuals (e.g., family history, age) or those with a positive FOBT. Colonoscopy aims to detect and remove precancerous polyps, reducing cancer risk [1].

However, colonoscopy's accuracy is limited by factors like endoscopist skill, bowel preparation, and fatigue, leading to missed or misdiagnosed polyps. While a high adenoma detection rate (ADR) is inversely correlated with cancer risk

[6], and visual assessment guides polyp management, challenging cases necessitate histopathology, incurring risks and costs. Meta-analyses document high missed polyp (22-27% [31, 36]) and missed cancer rates (up to 8

To address these limitations, AI-powered polyp detection and classification have advanced rapidly. Machine- and deep-learning models show impressive results in retrospective and prospective studies [4], and randomized controlled trials confirm CAdE system effectiveness. A meta-analysis projects a 52% ADR increase [22], significantly improving cancer detection. Consequently, manufacturers are deploying commercial AI products offering real-time visual assistance. However, despite these promising results, integrating AI into clinical practice raises concerns. Early-adopter endoscopists report AI fatigue from information overload [14] and express concerns about the lack of AI model transparency, potentially leading to incorrect recommendations and patient harm.

This paper shares our experience developing AI-assisted colonoscopy systems in Australia over the past two years, targeting the HCI community. We have developed multiple machine learning models for both upper and lower gastrointestinal (GI) [3, 25, 26] and conducted a field study involving semi-structured interviews with three gastroenterologists of varying experience levels at a local hospital. This research aimed to understand the specific needs of these clinicians. AI-assisted colonoscopy systems occupy a unique position: while the underlying AI algorithms are sufficiently robust to gain regulatory approval for clinical use and assist in high-stakes decision-making, the usability of these systems is often considered poor by clinicians [14]. We believe the field of AI-assisted colonoscopy urgently requires the attention of the HCI community. Incorporating a human-centered design approach can significantly increase clinician adoption and acceptance, ultimately leading to better patient outcomes both in Australia and globally.

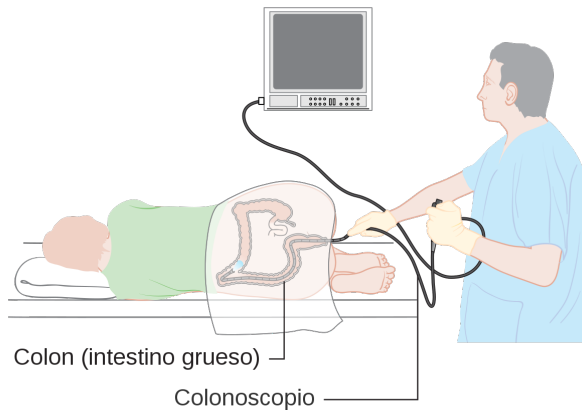


Figure 1: The colonoscopy procedure diagram.

2 BACKGROUND AND RELATED WORK

Colorectal cancer (CRC), a common malignancy of the digestive tract, develops in the colon. In Australia (2019), it was the second most commonly diagnosed cancer and the deadliest, with 16,398 new cases and 5,597 deaths [18]. CRC typically originates as polyps – flat, raised, stalked, or carpet-like growths along the colonic lumen.

Colonoscopy is the most effective method for reducing colorectal cancer incidence and mortality [1]. During this 30-60 minute procedure, a fiber-optic camera on a flexible tube (Figure 1) examines the colon, displaying video on an external screen for visual diagnosis. Endoscopists visually assess discovered polyps as hyperplastic, adenomatous, or malignant, determining subsequent management. If a reliable optical diagnosis is impossible, histopathological assessment of biopsied or resected polyps is required, a practice carrying risks, inefficiencies, and high costs.

Polyp detection and classification accuracy depend on endoscopist factors (experience, fatigue), operational factors (bowel preparation, withdrawal time), and lesion characteristics [15]. While new endoscopic technologies like high-definition colonoscopy, narrow-band imaging (NBI), and intelligent color enhancement have improved visualization [10, 16, 24], their impact on polyp detection remains controversial due to the need for more experienced endoscopists, longer procedure times, and increased costs.

Computer-Aided Detection of Polyps

Early research explored computer-aided colonoscopy, analyzing video alongside the endoscopist [7, 27, 37]. Deep learning now dominates CAde, outperforming traditional methods in competitions like MICCAI 2015 [2]. For a CAde overview, see Kumar et al. [11] and the "Awesome Polyp Segmentation"

repository [38]. Recent work focuses on real-time, efficient deep learning, primarily CNNs. Studies use datasets like Kvasir-SEG, with new architectures (e.g., ColonSegNet [28]) balancing accuracy and speed. Lightweight models like Enhanced NanoNet [9] and Jha et al.'s [5] improve segmentation with minimal computation, achieving high Dice scores [12].

Few works investigated colonoscopy using HCI methodologies. Van Berkel et al. [29] evaluated seven visual markers for polyp detection and concluded that the clinicians preferred blue wide bounding circles. Notably, the experiment did not assess the position map design from the CAD EYE system (Figure 2 b). AI-assisted colonoscopy has also been discussed as a case study under the theme of continuous human-AI interaction [30, 35].

Commercial AI-assisted Colonoscopy Systems

Driven by impressive AI model results, several commercial AI-assisted colonoscopy systems have emerged, including Medtronic¹, the *EndoBRAIN* by Cybernet², *AI4GI* by Satisfai³, and the *CAD EYE* from Fujifilm⁴. These systems integrate as extension modules with existing Olympus or Fujifilm endoscopes, taking video input and performing real-time polyp detection using CNN-based algorithms, often with YOLO-based tracking [13]. CAde assistance varies (Figure 2), but all overlay information directly onto the endoscope video stream. GI-Genius and AI4GI use bounding boxes around detected polyps (Figure 2a). *EndoBRAIN* avoids visual obstruction by using alert sounds and yellow corner highlights. *CAD EYE* offers multiple options: bounding boxes, a visual assistance circle, and a separate position map (Figure 2b). Furthermore, *EndoBRAIN-plus* and *CAD EYE* Characterisation provide real-time polyp classification (non-neoplastic/adenoma/invasive cancer for *EndoBRAIN-plus*; hyperplastic/neoplastic for *CAD EYE*), displaying results textually alongside the video.

3 FIELD STUDY AND PROJECT EXPERIENCE

We conducted a field study at Lyell McEwin Hospital, South Australia, to understand colonoscopy procedures and the potential for AI assistance. A team (one UX designer and two AI researchers) observed a 30-minute colonoscopy performed by a senior gastroenterologist, assisted by a junior gastroenterologist, nurse, and anesthetist, using an Olympus X1 system with a 4K display. This procedure did not include AI assistance, which remains uncommon in Australia. Following the observation, we conducted separate

¹<https://www.medtronic.com/covidien/en-us/products/gastrointestinal-artificial-intelligence/gi-genius-intelligent-endoscopy.html>

²<https://www.cybernet.co.jp/medical-imaging/products/endobrain/>

³<https://satisfai.health/gi-cancer-treatments>

⁴<https://fujifilm-endoscopy.com/cadeye>

Toward a Human-Centered AI-assisted Colonoscopy System

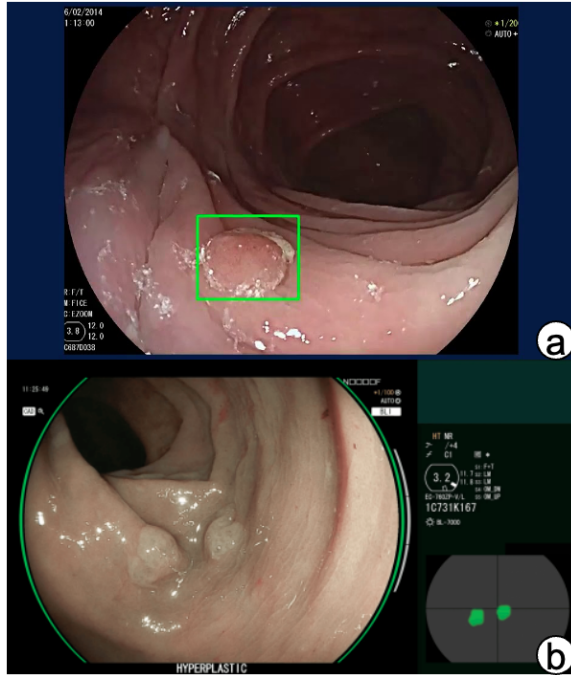


Figure 2: Commercial AI-assisted colonoscopy systems

semi-structured interviews with the senior gastroenterologist and two junior gastroenterologists (all specialist registrars familiar with CADe systems). The senior gastroenterologist had experience with Fujifilm’s CAD EYE system. Interview questions are listed in Appendix A. Subsequently, we held several follow-up meetings with both the gastroenterologists and potential commercial partners to discuss system sketches and the potential technology transfer of the team’s AI models [3, 26].

4 RESULT AND DISCUSSION

This section reports our initial findings from the field study and insights gained during subsequent discussions.

Colonoscopy Procedure

We summarise the colonoscopy procedure learned from the direct observation and the interview in Figure 3. The colonoscopy procedure begins with the endoscopist inserting the endoscope into the colon. Through the visual inspection, the endoscopist needs to continue the intubation until the endoscope reaches the caecum, i.e. the tip of the endoscope touches the appendiceal orifice. After reaching the caecum, the endoscopist slowly withdraws the endoscope and examines the colon’s inner lining. When the endoscopist found a polyp, the endoscopist would maneuver the endoscope for a close-up view of the polyp and takes a screenshot for documentation. The endoscopist then classifies the polyp based

on the visual inspection and decides a treatment, such as no intervention or removal and retrieval for pathology analysis. The polyp detection, diagnosis, and treatment process continues until the endoscope is wholly withdrawn. After the procedure is completed, the endoscopists then sit in front of a computer and compile a comprehensive colonoscopy report based on the captured photos during the colonoscopy. The report includes essential information such as assessments of patient risk and comorbidity, the findings of polyps and interventions, and the follow-up plan.

Polyp Detection and Classification (Q1, Q2, Q3, Q6)

Gastroenterologists identified polyp shape, location, and type as key factors influencing detection difficulty. Small, flat, or sessile serrated adenomas are challenging. Polyps behind folds, in blind areas (medical wall of ascending colon, hepatic flexure, between appendiceal orifice and ileocecal valve, rectosigmoid junction), far from the endoscope, or at the periphery of view are also harder to detect.

A case difficult for an endoscopist might be simple for AI, and vice-versa. For example, a tiny polyp, hard to see for a human, might be clear to an AI in a 4K image. Conversely, AI might be confused by lighting, feces, or water, while a trained endoscopist would not. Further research should investigate context-aware AI assistance.

Interviewees emphasized the importance of combined polyp detection and classification. Endoscopic societies advocate for >90% accuracy in optical diagnosis to enable cost-effective strategies (e.g., ignoring small, benign hyperplastic polyps; discarding resected adenomas without histopathology) [20]. General endoscopists often struggle to achieve this, necessitating removal and histopathological diagnosis of all polyps. An AI system capable of expert-level diagnosis based on multiple features could save significant medical resources.

Quality Assurance (Q4, Q5, Q7)

Beyond polyp detection and classification, interviewees suggested using AI to audit colonoscopy procedures. Factors like poor withdrawal technique, short withdrawal time, inadequate bowel preparation, and failure to intubate the cecum can lead to missed polyps, regardless of AI assistance. An AI could monitor withdrawal time (optimally >7 minutes) by recognizing cecal landmarks. It could also gather contextual data (polyp count, removal times, locations) to provide feedback and ensure adherence to standards. Furthermore, interviewees desired AI automation of routine tasks: capturing polyp screenshots at varying distances/angles, estimating polyp size (correlating with cancer risk), and, ultimately, generating comprehensive procedure reports using natural

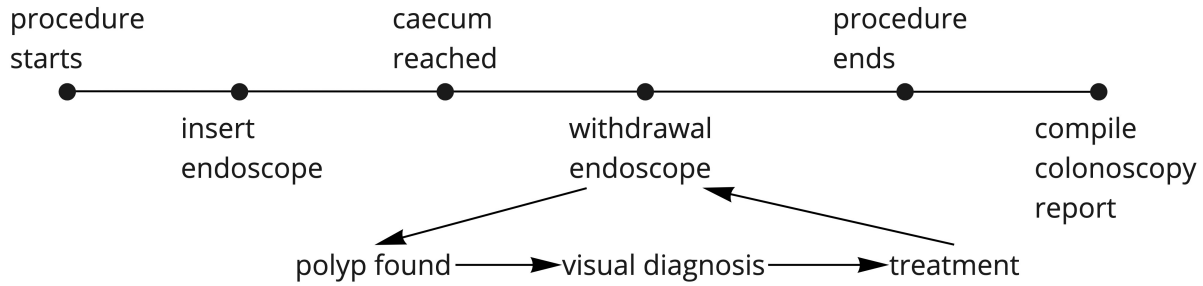


Figure 3: The colonoscopy procedure

language. While research exists on medical information extraction from reports [34] and automated pathology report generation [19], colonoscopy procedure report generation remains largely unexplored.

More Challenges in AI-Assisted Colonoscopy

Randomized controlled trials show AI-assisted colonoscopy can increase ADR to 36.6% (vs. 25.2% without AI). A 4% ADR increase reduces colorectal cancer rates by 1% in follow-up exams [6], suggesting AI use might become preferred or even legally required. However, current legal frameworks hold domain experts accountable for their decisions and patient safety [21]. Thus, AI systems must not only aid in polyp detection/classification but also assist endoscopists in explaining, justifying, and taking responsibility for their decisions.

Conversely, over-reliance on AI could lead to negative outcomes, such as endoscopists relaxing their polyp search. Superior AI performance might also reduce junior doctors' confidence and lead to deskilling [23]. Future studies should explore the effects of prolonged AI assistance and optimal training methods.

Australia faces unique challenges due to urban/rural disparities in resources and demographics. AI model training data, primarily from urban teaching hospitals, may introduce bias, affecting accuracy. Rural hospitals with older, lower-resolution equipment may also present challenges to AI model validity. Similar to HCI research in developing countries [8, 33] and AI use in rural healthcare [32], addressing data and demographic biases is crucial for equitable AI-enabled colonoscopy in Australia.

The Need for Integrated Design in AI-Assisted Colonoscopy

Gastroenterologists we interviewed primarily focused on the machine learning model's performance, giving less consideration to user interface design. Industry partners exhibited a similar pattern: large healthcare companies prioritized data

and annotation acquisition, while start-ups planned to address user experience internally, despite their interest in the AI models. This suggests a tendency to treat the AI algorithm and the user interface as separate entities, rather than as integral components of a single system. This separation, while understandable from a purely technical perspective, neglects the crucial interplay between algorithmic accuracy and user interaction, a core principle of HCI [17]. The effectiveness of AI-assisted colonoscopy depends not just on what the AI can do, but on how endoscopists can effectively interact with and interpret its output. The HCI community needs to advocate for a more integrated approach, where user needs and workflow considerations are incorporated from the earliest stages of AI development. Encouragingly, Australian funding agencies are increasingly valuing co-design and user-centered approaches in medical technology, indicating a potential shift towards more holistic AI development.

5 CONCLUSION

AI-assisted colonoscopy holds significant promise for improving colorectal cancer detection and management, as evidenced by advances in polyp detection, classification, and procedural documentation. However, our field study and analysis reveal critical challenges that must be addressed to realize this potential fully. These include concerns about the impact of prolonged AI use on endoscopist skill, the need for robust quality assurance measures, and the potential for data bias to exacerbate existing healthcare disparities, particularly in rural Australia. Moreover, the prevailing emphasis on algorithmic accuracy over user experience underscores the vital role of HCI in ensuring that these systems are designed for seamless integration into clinical workflows and are truly supportive of endoscopist expertise. A collaborative, human-centered approach, bringing together HCI researchers, AI researchers, clinicians, and industry, is essential to navigating these challenges and maximizing the benefits of AI for the society.

Toward a Human-Centered AI-assisted Colonoscopy System

REFERENCES

- [1] Australian Institute of Health and Welfare. 2024. Cancer data in Australia. Web report. <https://www.aihw.gov.au/reports/cancer/cancer-data-in-australia>
- [2] Jorge Bernal, Nima Tajbaksh, Francisco Javier Sanchez, Bogdan J Matuszewski, Hao Chen, Lequan Yu, Quentin Angermann, Olivier Romain, Bjørn Rustad, Ilanko Balasingham, et al. 2017. Comparative validation of polyp detection methods in video colonoscopy: results from the MICCAI 2015 endoscopic vision challenge. *IEEE transactions on medical imaging* 36, 6 (2017), 1231–1249.
- [3] David Butler, Yuan Zhang, Tim Chen, Seon Ho Shin, Rajvinder Singh, and Gustavo Carneiro. 2022. In Defense of Kalman Filtering for Polyp Tracking from Colonoscopy Videos. *International Symposium of Biomedical Imaging* (2022).
- [4] Cesare Hassan, Marco Spadaccini, Andrea Iannone, Roberta Maselli, Manol Jovani, Viveksandeep Thoguluva Chandrasekar, Giulio Antonelli, Honggang Yu, Miguel Areia, Mario Dinis-Ribeiro, Pradeep Bhandari, Prateek Sharma, Douglas K Rex, Thomas Rösch, Michael Wallace, and Alessandro Repici. 2021. Performance of artificial intelligence in colonoscopy for adenoma and polyp detection: a systematic review and meta-analysis. *Gastrointest. Endosc.* 93, 1 (Jan. 2021), 77–85.e6.
- [5] Debesh Jha, Shehroz H. Ali, Michael A. Riegler, Pål Halvorsen, Dag Johansen, Thomas de Lange, Konstantin Pogorelov, Henrik K. Stensland, Duc-Tien Nguyen, Carsten Griwodz, et al. 2024. Lightweight Deep Learning Model for Real-Time Colorectal Polyp Segmentation. *Journal of Imaging* 12, 9 (2024), 1962. <https://doi.org/10.3390/jimaging10050144>
- [6] Michal F Kaminski, Paulina Wieszczy, Maciej Rupinski, Urszula Wojciechowska, Joanna Didkowska, Ewa Kraszevska, Jaroslaw Kobiela, Robert Franczyk, Maria Rupinska, Bartlomiej Kocot, Anna Chaber-Ciopinska, Jacek Pachlewski, Marcin Polkowski, and Jaroslaw Regula. 2017. Increased Rate of Adenoma Detection Associates With Reduced Risk of Colorectal Cancer and Death. *Gastroenterology* 153, 1 (July 2017), 98–105.
- [7] Stavros A Karkanis, George D Magoulas, Dimitrios K Iakovidis, DA Karras, and DE Maroulis. 2001. Evaluation of textural feature extraction schemes for neural network-based interpretation of regions in medical images. In *Proceedings 2001 International Conference on Image Processing (Cat. No. 01CH37205)*, Vol. 1. IEEE, 281–284.
- [8] Naveena Karusala, Ding Wang, and Jacki O'Neill. 2020. Making chat at home in the hospital: Exploring chat use by nurses. In *Proceedings of the 2020 chi conference on human factors in computing systems*. 1–15.
- [9] M. A. Khan, M. Sharif, T. Akram, M. A. Khan, M. Irfan, N. Muhammad, A. Rehman, M. I. Razzak, and S. A. C. Bukhari. 2024. Enhanced accuracy with Segmentation of Colorectal Polyp using NanoNetB, and Conditional Random Field Test-Time Augmentation. *Frontiers in Robotics and AI* 11 (2024), 1387491. <https://doi.org/10.3389/frobt.2024.1387491>
- [10] Nam Hee Kim, Yoon Suk Jung, Woo Shin Jeong, Hyo-Joon Yang, Soo-Kyung Park, Kyuyong Choi, and Dong Il Park. 2017. Miss rate of colorectal neoplastic polyps and risk factors for missed polyps in consecutive colonoscopies. *Intestinal research* 15, 3 (2017), 411.
- [11] S. Kumar, L. Hussain, A. Mehmood, N. Kumar, B. Kumar, A. Sharma, N. Goyal, A. K. Singh, P. Singh, R. Verma, et al. 2023. Detection of Colorectal Polyps from Colonoscopy Using Machine Learning: A Survey on Modern Techniques. *Journal of Personalized Medicine* 13, 2 (2023), 295. <https://doi.org/10.3390/jpm13020295>
- [12] Po-Wei Lin, Philip Wai-Yan Chiu, Ming-Shiang Wu, Jung-Shun Hung, and Yu-Jen Chen. 2022. A Machine Learning-Based System for Real-Time Polyp Detection (DeFrame): A Retrospective Study. *Frontiers in Medicine* 9 (2022), 852553. <https://doi.org/10.3389/fmed.2022.852553>
- [13] Li Liu, Wanli Ouyang, Xiaogang Wang, Paul Fieguth, Jie Chen, Xinwang Liu, and Matti Pietikäinen. 2020. Deep learning for generic object detection: A survey. *International journal of computer vision* 128, 2 (2020), 261–318.
- [14] Yuichi Mori, Helmut Neumann, Masashi Misawa, Shin-Ei Kudo, and Michael Bretthauer. 2021. Artificial intelligence in colonoscopy - Now on the market. What's next? *J. Gastroenterol. Hepatol.* 36, 1 (Jan. 2021), 7–11.
- [15] B Murphy, E Myers, T O'Shea, K Feeley, and B Waldron. 2020. correlation between adenoma detection rate and polyp detection rate at endoscopy in a non-screening population. *Scientific Reports* 10, 1 (2020), 1–6.
- [16] Aleksandar Nagorni, Goran Bjelakovic, and Bratislav Petrovic. 2012. Narrow band imaging versus conventional white light colonoscopy for the detection of colorectal polyps. *Cochrane Database of Systematic Reviews* 1 (2012).
- [17] Donald A. Norman. 2013. *The Design of Everyday Things: Revised and Expanded Edition*. Basic Books.
- [18] Jennifer Pan, Masha Slattery, Natalie Shea, and Finlay Macrae. 2019. Outcomes of screening and surveillance in people with two parents affected by colorectal cancers: experiences from the Familial Bowel Cancer Service.(Report). *Hereditary Cancer in Clinical Practice* 17, 1 (2019), 25.
- [19] Gottumukkala S Raju, Phillip J Lum, Rebecca S Slack, Selvi Thirumurthi, Patrick M Lynch, Ethan Miller, Brian R Weston, Marta L Davila, Manoop S Bhutani, Mehnaz A Shafi, et al. 2015. Natural language processing as an alternative to manual reporting of colonoscopy quality metrics. *Gastrointestinal endoscopy* 82, 3 (2015), 512–519.
- [20] Colin J Rees, Praveen T Rajasekhar, Ana Wilson, Helen Close, Matthew D Rutter, Brian P Saunders, James E East, Rebecca Maier, Morgan Moorghen, Usman Muhammad, et al. 2017. Narrow band imaging optical diagnosis of small colorectal polyps in routine clinical practice: the Detect Inspect Characterise Resect and Discard 2 (DISCARD 2) study. *Gut* 66, 5 (2017), 887–895.
- [21] David Schneeberger, Karl Stöger, and Andreas Holzinger. 2020. The European Legal Framework for Medical AI. In *Machine Learning and Knowledge Extraction*. Springer International Publishing, 209–226.
- [22] Sagar Shah, Nathan Park, Nabil El Hage Chehade, Anastasia Chahine, Marc Monachese, Amelie Tiritilli, Zain Moosvi, Ronald Ortizo, and Jason Samaraseena. 2023. Effect of computer-aided colonoscopy on adenoma miss rates and polyp detection: a systematic review and meta-analysis. *Journal of Gastroenterology and Hepatology* 38, 2 (2023), 162–176.
- [23] Emanuele Sinagra, Francesca Rossi, and Dario Raimondo. 2021. Use of artificial intelligence in endoscopic training: Is deskilling a real fear? *Gastroenterology* 160, 6 (2021), 2212.
- [24] V Subramanian, J Mannath, CJ Hawkey, and K Ragunath. 2011. High definition colonoscopy vs. standard video endoscopy for the detection of colonic polyps: a meta-analysis. *Endoscopy* 43, 06 (2011), 499–505.
- [25] JL Tan, D Pitawela, A Chinnaratha, H-T Chen, G Carneiro, and R Singh. 2023. Enhancing accuracy in Barrett's surveillance using artificial intelligence: A multimodal (white-light and narrow-band imaging) model comparing vision transformer and convolutional neural networks. (2023).
- [26] Jin L Tan, Dileepa Pitawela, Mohamed A Chinnaratha, Andrawus Beany, Enrik J Aguila, Hsiang-Ting Chen, Gustavo Carneiro, and Rajvinder Singh. 2024. Exploring vision transformers for classifying early Barrett's dysplasia in endoscopic images: A pilot study on white-light and narrow-band imaging. *JGH Open* 8, 9 (2024), e70030.
- [27] Marta P Tjoa and Shankar M Krishnan. 2003. Feature extraction for the analysis of colon status from the endoscopic images. *BioMedical*

- Engineering OnLine* 2, 1 (2003), 1–17.
- [28] M. N. Tuba and J. Saleem. 2021. Real-Time Polyp Detection, Localization and Segmentation in Colonoscopy Using Deep Learning. *Diagnostics* 11, 2 (2021), 295. <https://doi.org/10.3390/diagnostics11020295>
 - [29] Niels van Berkel, Omer F Ahmad, Danail Stoyanov, Laurence Lovat, and Ann Blandford. 2021. Designing Visual Markers for Continuous Artificial Intelligence Support. , 24 pages.
 - [30] Niels Van Berkel, Jeremy Opie, Omer F Ahmad, Laurence Lovat, Danail Stoyanov, and Ann Blandford. 2022. Initial Responses to False Positives in AI-Supported Continuous Interactions: A Colonoscopy Case Study. *ACM Trans. Interact. Intell. Syst.* 12, 1 (March 2022), 1–18.
 - [31] Jeroen C van Rijn, Johannes B Reitsma, Jaap Stoker, Patrick M Bossuyt, Sander J van Deventer, and Evelien Dekker. 2006. Polyp miss rate determined by tandem colonoscopy: a systematic review. *Am. J. Gastroenterol.* 101, 2 (Feb. 2006), 343–350.
 - [32] Dakuo Wang, Liuping Wang, Zhan Zhang, Ding Wang, Haiyi Zhu, Yvonne Gao, Xiangmin Fan, and Feng Tian. 2021. “Brilliant AI Doctor” in Rural Clinics: Challenges in AI-Powered Clinical Decision Support System Deployment. In *Proceedings of the 2021 CHI Conference on Human Factors in Computing Systems* (Yokohama, Japan) (CHI '21, Article 697). Association for Computing Machinery, New York, NY, USA, 1–18.
 - [33] Liuping Wang, Dakuo Wang, Feng Tian, Zhenhui Peng, Xiangmin Fan, Zhan Zhang, Mo Yu, Xiaojuan Ma, and Hongan Wang. 2021. Cass: Towards building a social-support chatbot for online health community. *Proceedings of the ACM on Human-Computer Interaction* 5, CSCW1 (2021), 1–31.
 - [34] Yanshan Wang, Liwei Wang, Majid Rastegar-Mojarad, Sungrim Moon, Feichen Shen, Naveed Afzal, Sijia Liu, Yuqun Zeng, Saeed Mehrabi, Sunghwan Sohn, et al. 2018. Clinical information extraction applications: a literature review. *Journal of biomedical informatics* 77 (2018), 34–49.
 - [35] Philipp Wintersberger, Niels van Berkel, Nadia Fereydooni, Benjamin Tag, Elena L Glassman, Daniel Buschek, Ann Blandford, and Florian Michahelles. 2022. Designing for Continuous Interaction with Artificial Intelligence Systems. In *CHI Conference on Human Factors in Computing Systems Extended Abstracts* (New Orleans, LA, USA) (CHI EA '22, Article 170). Association for Computing Machinery, New York, NY, USA, 1–4.
 - [36] Shengbing Zhao, Shuling Wang, Peng Pan, Tian Xia, Xin Chang, Xia Yang, Liliangzi Guo, Qianqian Meng, Fan Yang, Wei Qian, Zhichao Xu, Yuanqiong Wang, Zhijie Wang, Lun Gu, Rundong Wang, Fangzhou Jia, Jun Yao, Zhaoshen Li, and Yu Bai. 2019. Magnitude, Risk Factors, and Factors Associated With Adenoma Miss Rate of Tandem Colonoscopy: A Systematic Review and Meta-analysis. *Gastroenterology* 156, 6 (May 2019), 1661–1674.e11.
 - [37] MM Zheng, SM Krishnan, and Marta P Tjoa. 2005. A fusion-based clinical decision support for disease diagnosis from endoscopic images. *Computers in Biology and Medicine* 35, 3 (2005), 259–274.
 - [38] Tao Zhou. 2024. Awesome Polyp Segmentation. GitHub repository. <https://github.com/taozh2017/Awesome-Polyp-Segmentation> Accessed: [Your Access Date - e.g., 2024-09-27].

A QUESTIONS FOR THE SEMI-STRUCTURED INTERVIEW

AI-Assisted Colonoscopy - During Procedure

- Q1. What kind of polyps are most challenging for an endoscopist to detect or characterize?

- Q2. What kind of information from AI can assist you in such challenging situations?
- Q3. What are the common mistakes you have found with junior endoscopists? What type of assistance would a junior endoscopist often need during the procedure?
- Q4. During the procedure, the endoscopist constantly engages in multiple tasks such as searching for polyps, cleaning up the colon with water, characterizing polyps, and removing polyps. Are there other frequent tasks that you think AI can assist?
- Q5. AI can automatically analyze and record different events in the procedure. For example, an AI can automatically record the number of polyps detected, the amount of time for each polyp removal, or automatically take photos of the polyps. Would such functions be useful to you? Are there anything that you hope AI can automate for you?
- Q6. What is the last thing you want AI to do during the procedure?

AI-Assisted Colonoscopy - After-Procedure

- Q7. After the procedure, the endoscopist needs to compile and annotate the procedure record. What are the common difficulties you encounter at this step? Is there anything that you wish could be automated?