

Cytology Image Analysis Techniques Towards Automation: Systematically Revisited

Shyamali Mitra^{*}, Nibaran Das[†], Soumyajyoti Dey[‡]
Sukanta Chakrabarty[§], Mita Nasipuri[¶], Mrinal Kanti Naskar^{||}

March 18, 2020

Abstract

Cytology is the branch of pathology which deals with the microscopic examination of cells for diagnosis of carcinoma or inflammatory conditions. Automation in cytology started in the early 1950s with the aim to reduce manual efforts in diagnosis of cancer. The inflush of intelligent technological units with high computational power and improved specimen collection techniques helped to achieve its technological heights. In the present survey, we focus on such image processing techniques which put steps forward towards the automation of cytology. We take a short tour to 17 types of cytology and explore various segmentation and/or classification techniques which evolved during last three decades boosting the concept of automation in cytology. It is observed, that most of the works are aligned towards three types of cytology: Cervical, Breast and Lung, which are discussed elaborately in this paper. The user-end systems developed during that period are summarized to comprehend the overall growth in the respective domains. To be precise, we discuss the diversity of the state-of-the-art methodologies, their challenges to provide prolific and competent future research directions inbringing the cytology-based commercial systems into the mainstream.

1 INTRODUCTION

Cancer, as of now, has become a soaring concern in individuals. Living organisms are composed of large number of cells. Normal cells have specific lifetime in which they reproduce and divide to produce new cells, replacing the old ones. Before the old cells worn out it passes its genetic information to the new

^{*}Department of Instrumentation and Electronics Engineering, Jadavpur University

[†]Department of Computer Science & Engineering, Jadavpur University

[‡]Department of Computer Science & Engineering, Jadavpur University

[§]Theism Medical Diagnostics Centre

[¶]Department of Computer Science & Engineering, Jadavpur University

^{||}Department of Electronics & Telecommunication Engineering, Jadavpur University

ones. Thus, cell divisions are initiated by a control signal generated from a specific protein called cyclins. But, cancer cells divide in a proliferative manner thereby violating coordination among cells. Though cancer causing genes are inherited genetically, various external factors like indulging in smoking and drinking, exposure to heavy metals, radiation, usage of plastics etc. [27] are also responsible for this. Cancer cells have several distinguishing characteristics from benign cells that are extensively discussed in different types of cytology. More specifically, the study of tissues and cells using a microscope to detect malignancies or other inflammatory conditions is broadly categorized under cytology or cell biology. There are several challenges in analyzing cytology images which make the overall diagnosis process difficult even by a trained and experienced cytotechnologists. The challenge percolates from nuclear shape, size, density to diverse nature of cytoplasm [25]. There are different automatic or semi-automatic systems [153, 193, 19, 76, 180, 47, 46, 91, 206] to aid cytotechnologists in the diagnosis procedure. The existing survey papers [100, 137, 181] address the segmentation and classification problem for a single domain in cytology. Also it is observed that meagre attention is given to cytology compared to histopathology despite its potential to classify a malignancy cell in the least invasive manner. Therefore, it is very difficult to gather an overall knowledge about the entire domain of cytology, related to the challenges and the limitations. This provoked the idea of excavating cytology based research works to give better pace in this domain. In this paper, we attempt to produce a comprehensive list of 17 different types of cytology based on their sites of origin. We also discuss a large pool of segmentation and classification algorithms with associated challenges in meeting higher performance requirements, outline techniques to address common bottlenecks, correlation between them and provide meaningful insights on the techniques for future developments for automation in the diagnosis process. The research works over past 30 years in these domains of cytology are systematically and extensively reviewed so that one can have a deeper insight into the evolution of methodologies. The highlights of the present survey illustrated is given in Fig.1. In section 2, we provide a brief introduction to cytology. In section 3, we discuss automation in cytology and its underlying principles of image analysis. In section 4, we discuss briefly about 17 different types of cytology and undergo a concise and comprehensive survey on three different domains of cytology viz. cervical, breast, and lung, where extensive research works on the advanced techniques for segmentation and classification problems are carried out. Other types of cytology are grouped under miscellaneous section. In section 5, we mentioned the state-of-the-art systems developed to comprehend overall progress in the respective domains. A section based on authors' view is presented to discuss concisely about the comprehensive progress of cytology image analysis techniques.

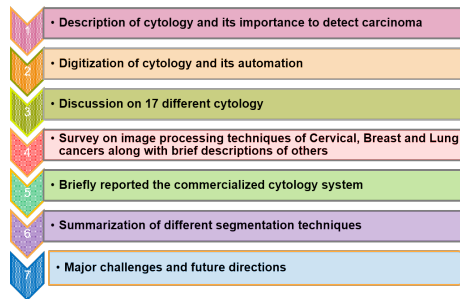


Figure 1: Highlights of the present Survey

2 CYTOLOGY: A BRIEF INTRODUCTION

The body of an organism is comprised of millions and trillion of cells. Each cell possesses a cytoplasm and a nucleus. Cytoplasm or the cell body acts as an envelope to the nucleus containing chromosomes, the genetic material that undergoes mutation under certain changes in the form of diseases. The changes are reflected in the morphology of nucleus and cytoplasm. Thus, the micro examination of cells, can unfold relevant information on any morphological alteration in response to a particular disease. These cells, which are important predictors of pre-malignant and malignant lesions, can be sampled and examined under the microscope to diagnose different medical conditions with the exception of a few. Cytology test is an easy option for the patients because of its painless procedure to detect the disease and also an attractive option for the doctors because it is easier to treat the disease at the nascent stage. In certain tests, [124] cytology is sensitive to potentially high grade tumors and cytology when combined with other modalities of testing can increase the sensitivity of detection to a greater extent.

In benign cells, the cellular materials are generally well-defined, exhibiting uniform chromatin distribution within the nucleus and a prominent cytoplasm. The nucleus boundary is usually regular and nearly elliptical in shape. Malignant cells, on the other hand, possess irregular nuclear boundary. Scanty cytoplasm and multiple nuclei with unusual sizes can be observed in a single cell. For classifying a specimen into benign and malignant, these characteristics are usually taken under consideration.

Histopathology gives information of tissue for further immunohistological and molecular analysis needed for targeted cancer chemotherapy. In breast cancer, Fine Needle Aspiratuin Cytology (FNAC) is pretty good in diagnosing carcinoma and benign fibroadenomas, but histopathology needs some borderline and stromal lesions. In thyroid cell carcinoma, FNAC can diagnose almost all types of goitre, thyroiditis, papillary carcinoma, medullary carcinoma etc. Histopathology, on the other hand, is necessary to differentiate follicular adenoma and carcinoma. In lung cancer, FNAC is best suited to detect infections and primary diagnosis of cancers. Histopathology of lung may be harmful in some

infective conditions like tuberculosis etc.

Two types of cytology tests are undertaken to determine presence of carcinoma and if detected, figures out the extent of disease. A screening test may be performed at regular intervals to assure the presence of disease. It is helpful to detect the disease at an infant stage when response to the treatment is faster and easier so that chances of fatality is reduced. It is generally recommended for those who are highly prone to this disease. A diagnostic test is done when signs or symptoms are more common. This test is carried out to check the presence of disease and if so, aimed at precise identification of the specific condition of the disease.

Preceding to any screening or the diagnostic test, the specimen needs to be prepared. The preparation consists of three steps: i) Specimen collection, ii) Slide Preparation and iii) Fixation, which are described in detail in supplementary section.

3 PRINCIPLES OF CYTOLOGY IMAGE ANALYSIS

After a suitable slide is prepared, a screening or a diagnostic test can be performed for the identification of the specimen. It can be done manually or through automated CAD based system. A manual screening procedure directly involves an expert cytotechnologist to review/examine the slides. Whereas, in automatic screening system, there are few steps that are handled by a computer using some image processing protocols. For automated systems, result is predicted by a locally installed or any remotely installed device without human counterpart. A comparative pictorial representation of manual and automatic screening system is given in Fig. 2. It is worthy to mention here that there are certain factors

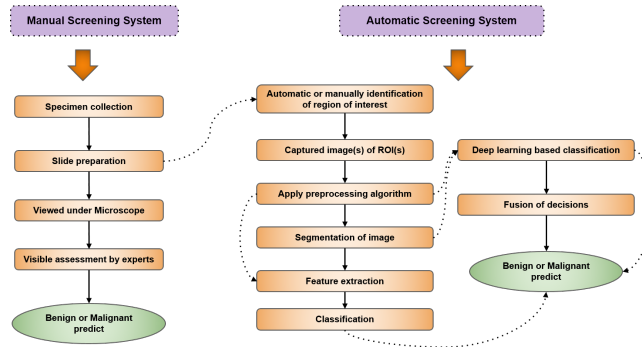


Figure 2: Pictorial representation of manual and automatic malignant screening system

that hinder the proper interpretation of slide leading to an erroneous result. Such factors include: a) Sample inadequacy or fewer number of malignant cells,

b) Poor preparation of slide. Slide may contain excessive blood, mucus, inflammatory cells, background necrosis or other foreign particles and obscuring materials making overall appearance can unclear and cloudy, c) Poorly smeared or stained, d) Poor preservation of slides, e) Lack of experience of pathologists to collect the specimen from the exact location of the tumor, All these factors give rise to what is known as sampling error or otherwise stated purging of these errors is a prerequisite for exact rendition of a sample.

3.1 The automation as a growing concept in cytology

Since long back, image analysis using visual interpretation has been the primary essence in cytological image analysis. The result is assessed based on the examination of cells under microscope by skilled practitioners which is a dearth as of now. Therefore, the objective behind the soaring trend of computer assisted diagnostic system is to reduce the time taken to perform the tests and complete the process of report generation. There are other factors like reducing the workload of cytotechnologists, human induced errors, allowing batch processing etc. which bolstered the motivations further to put steps forward towards automation. The aim to develop an automated screening system can be summarized into two categories:

- It can act as pre-screening system to differentiate a benign and a malignant specimen. To eradicate false negative cases, such systems must exhibit high false positive cases, so that, no single abnormal specimen demands further investigation by doctors are disregarded. Thus, in another sense, it can act as an adjunct to the cytotechnologists by eliminating the need of evaluating normal specimens, which saves time and energy as well.
- To run a parallel system to the present manual screening system. Thus, the diagnosis process can be bi-directed to produce less chances of errors at the specimen level after fusion.

The immediate impact of automation in cytology, that is realized by the entire community of doctors, is that it allows batch processing, eliminating the manual tiring and time consuming process. During early 1950's, the idea to develop 'Cytoanalyzer' [32], an automated scanning device, was the initial breakthrough to the concept of manual examination of slides. This could distinguish normal cells from abnormal cells using the information of nuclear size and optical density. However, the system suffered from two major disadvantages. The process was slow due to low processing power of the computers at that time. Apart from that, overlapping of cells and air drying factors of conventional pap smears complicated the identification procedure further with higher false positive rates. Atrophic changes in conventional smears of older patients added further hurdles to classify the images correctly by using automated analysis. So, there were several issues related to conventional pap smear slides which hindered the correct analysis by computer aided systems. To mitigate the issues, Zahniser et al. [198] came up with the idea of liquid cell suspension to

make “a better pap test” of the cervical sample. They used Feulgen stain rather than Papanicolaou stain. The software developed in conjunction with liquid based specimens gave better results with a dramatic decrease in false negative rates to 1% and false positive rates to 10%.

Another angle to successful implementation of automated screening system was to incorporate more shape and texture based features of nuclei and cytoplasm to achieve more accuracy and robustness. This idea was given a shape by Toshiba with the name of CYBEST [176]. It was a prototype developed in 1972 with further development in a new desk size design in 1981. AutoPap 300 and SurePath were two automated screening systems that were marketed successfully. Despite limited success achieved so far with the existing systems,

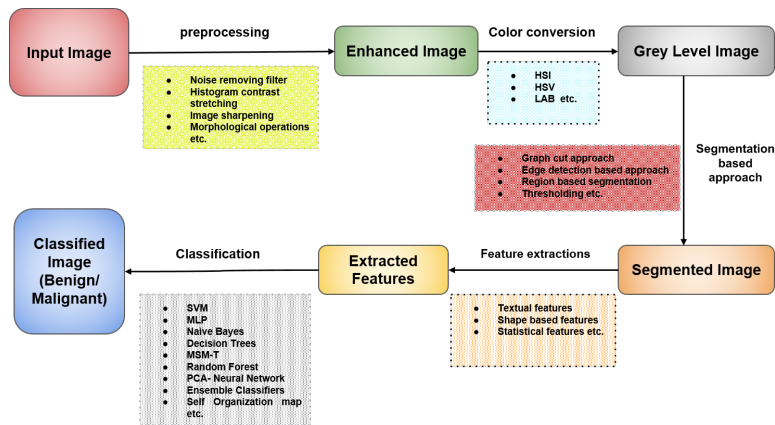


Figure 3: Image analysis steps of a typical segmentation based image processing system where the intermediate stages denote the processing techniques

there were constant efforts to upgrade and design automated screening systems on a large scale. There were a handful of designs developed during 1980’s like CERVISCAN [169], LEYTAS [3], FAZYTAN [38], BioPEPR [122] etc.

In cytology laboratories there are three major sections where automations are extremely pertinent and devices are currently accessible as follows:

- Specimen preparation devices: Two FDA(Food and Drug Administration) approved automated systems namely, ThinPrep Processor and the AutoCyte Prep serve the purpose popularly. ThinPrep processor 5000 uses thin prep technology, for cell dispersion, collection and transfer, which can process approximately 35 slides/hour. The preparation of monolayer slides in AutoCyte prep is done using liquid based preparations.
- Manual screening adjunctive devices: These devices are used either independently or in conjunction with human by focusing the portion of slides having abnormalities. Thus, examining the whole slide is not required. Some of the computerized FDA approved microscopes such as

CompuCyte's "M Pathfinder", Accumed International's "AcCell 2000" are widely used to mark abnormal cells.

- Automated screening devices: To automate the process the interpretation of cytology smears, Auto pap screener system, an existing system is designed to present a portion of slide that is adequate for analysis by cytotechnologist, thus trimming their workload to go through whole specimen.

3.2 Image analysis steps

The journey towards automation has lead researchers to enunciate new image processing algorithms for better understanding and analysis of the images. During analysis of a cytology specimen, some basic steps need to be followed. In manual screening system of cytology images, the steps include, preparation of cytology specimen, feeding, fixing and adjusting the slide with required magnification in the microscope to identify the region of interest. After proper examination based on the nature of specimen opinion is given by experts. Thus, each of these steps involve a human effort. In automatic screening system, all the above steps required prior to image analysis can be automated or semi-automated, including image digitization, segmentation of the images, features extraction and finally providing the diagnostic information through judicious use of classifiers. Each of these steps as mentioned in Fig. 3 gives rise to a number of challenging research problems that is studied in great deal over the last half century since the achievements in the field took place. If the goal is to create an interactive system, some of the difficulties can be left over human operator to solve, but when a fully automated system is a goal, all the steps are needed to be addressed. In the next section, we focus only on automation techniques available in image analysis steps.

4 DIFFERENT TYPES OF CYTOLOGY

There are different types of cytology based on the originating site of the human body. In Table 1, we have summarized 17 such types of cytology along with the modalities are summarized. It has been observed that most of the automated approaches are devised for screening of Cervical, Breast and Lung cancer. Therefore, those three cytology are discussed in details. Each of the work discussed in the next section throws light on how succeeding works evolve to better and robust algorithms. This will help the reader to get an overview about the domain very quickly. Some images of different cytology domains are shown in Fig.4,5,6,7 for better understanding of the type of specimen.

Table 1: Different types of cytology with their modalities and corresponding overall performances in detecting carcinoma

SL#	Cytology	Used to detect	Modality of specimen collection	Accuracy (Acc)/Sensitivity(Sen)/ Specificity(Sp)	Cytomorphology of benign cells (General characteristics irrespective of sub types)	Cytomorphology of malignant cells(General characteristics irrespective of sub types)	Limitations of cytology
1	Adrenal gland	To detect adrenal nodule.	Adrenal FNA	Acc : 96%-98%	a) Many naked nuclei. b) Granular background. c) Intact cells with fuzzy cytoplasm	a) Isolated cells with dense cytoplasm. b) Prominent nuclear atypia. c) Mitoses d) Background necrosis.	a) For nodules <3cm diagnostic accuracy drops
2	Breast	To detect breast tumors	a) Nipple discharge(ND). b) Ductal lavage using FNA.	ND : Se :41% - 60% FNA : Se :65% - 98% Sp :45%-100% F P :90% -2%	Round to oval monomorphic epithelial cell and adherent dark nucleus. (See Fig.7.1.a)	nuclei with irregular boundaries. b) Irregular spacing. c) Background debris. (See Fig.7.1.b)	a) Nipple discharge cytology is not very effective. b) It is performed to very few patients who are asymptomatic.
3	Cerebrospinal fluid	To detect malignancy	Lumbar puncture by using needle in intersubcostal space at L3 to L4 or L4 to L5.	Se :90% Sp : high	a) Sparsely cellular b) Round nuclei. c) Uniform nuclear contours	a) Irregular nuclear contours. b) Prominent nucleolus c) Abnormal chromatin pattern	a) Additional processing is needed to preserve the specimen
4	Cervical cytology	To detect cervical cancer	Scrape or brush cytology	Se :47% Sp :90%	Large polygonal cells with small round nuclei and large amount of eosinophilic cytoplasm. (See Fig.7.1.a)	Malignant melanoma a) Clusters of small cells. b) Scant cytoplasm c) Nuclear hyperchromasia (See Fig.7.1.b)	a) False positive cases are more. b) Less useful for cystic and fibrotic lesion
5	Gastrointestinal cytology	To evaluate gastro-intestinal tract lesions	Brush cytology	Se :77%-94% Sp :90%	a) Uniformly arranged cellular structure. b) Clear nuclear boundary. (See Fig.7.1.a)	a) Isolated cells and crowded groups. b) Nuclear pleomorphism c) Hyperchromasia. d) Irregular cell size and shape.	a) Sampling error. b) Accuracy compromised in deter-mining Barrett's esophagus. c) High false positive cases.
6	Kidney	To detect renal lesions	Renal FNA	Acc :73%- 94%	a) Large dense globular structures. b) Proximal tubular cells are rare	a) Large cells. b) Large nuclei. c) Abundant granular cytoplasm	a) FNAC has low sensitivity for small masses (<5cm) and complex cysts and large masses >5cm
7	Liver	To detect focal lesions of liver.	FNA	Se :71%-91% Sp :87% -100% Acc :86%-94%	Hepatocytes are large, polygonal, isolated cells with prominent nucleolus and bi-nucleated. They are centrally placed and round to oval in shape. (See Fig.4.1.a)	a) Isolated cells or cells in nest. Increased nucleus to cytoplasm ratio. b) Large round nucleus with prominent nucleolus. c) Often large naked nuclei present. (See Fig.4.1.b)	a) Rare hemorrhage, pain, bile peritonitis. b) Also, cannot typify the tumors
8	Lymph nodes	To confirm enlarged lymph nodes	FNA	Se : 80% Sp : 90% Acc : 93%	a) Dispersed isolated cell pattern. b) Presence of lymphoglandular bodies.	a) Polynorphous population. b) Mast cells present. (See Fig.4.1)	a) Sampling error. b) Cell vascular patterns are lost to some extent.
9	Ovarian lesions	To detect cyst ovarian masses	FNA	Se:(for borderline analysis) :84% - 93% Se : 26 - 40%	a) Sparsity to highly cellular. b) Cells possess round nucleus with coarsely granular chromatin with one or two small nucleoli.	a) Clusters and isolated cells. b) Large pleomorphic cells. c) Round nuclei with prominent nucleoli (See Fig.6.iii)	a) Higher false negative rates. b) Lesser reliability in distinguishing borderline tumor and carcinoma. c) Benign lesions not histologically categorized.
10	Pancreas and bile tree	To indicate a pancreatic mass and a duct stricture	FNA and Duct Brushings	FNA : Se : 86% -98% Sp : 100%	a) Round or oval nucleus. b) Evenly distributed nucleus c) Finely granulated chromatin. d) Cytoplasm boundaries well defined.	a) Moderate to high cellularity. b) Crowded sheets of disordered negative cases, ductal cells. c) Irregular nuclear contours. d) Enlarged nucleolus. e) Irregular chromatin distribution.	a) Sampling error can lead to false
11	Peritoneal washing	To detect spread of cancer in peritoneal surface	Washing cytology	F N :31%-86% F P : <3%	a) Isolated mesothelial cells in sheets, often folded. b) Pale chromatin. c) Small round or oval nuclei	a) Cell clusters and isolated cells. b) Enlarged nuclei, coarse chromatin. c) Nuclear pleomorphism d) Scant or abundant and vacuolated cytoplasm.	a) Sampling error
12	Pleural, Peri cardiac and Peritoneal fluid	To assess the fluid in diseased condition	FNA	Sp : High Se :71% F P :1% F N : High	a) Numerous cells often dispersed. b) Round nucleus with one nucleolus. c) Dense cytoplasm with clear boundary. (See Fig.5.1.a)	a) Numerous large clusters. b) Presence of cell block sections. c) Second population (See Fig.5.1.b)	a) False findings are high. b) Immuno-cytochemistry can act as companion to improve diagnostic accuracy.
13	Respiratory tract	To detect abnormalities in respiratory tract.	Sputum, Bronchial brushing, Transbronchial FNA, Trans esophageal FNA.	Sputum : Se :72% Sp :74% Transbronchial FNA : Se :91% Sp :96%-99% Acc :86% -85%	a) Large clusters of bronchial cells. b) Columnar cell with round nucleus and cytoplasm.	a) Polygonal, round, fibre like cells. b) Abundant dense and smudged cytoplasm filled with keratin. c) Small hyperchromatic nucleus. d) Inconspicuous nucleolus.	a) Accuracy of sputum cytology is low and susceptible to location in malignancy due to low epithelial cells. b) Fails to subclassify malignancies in adenocarcinoma
14	Salivary gland	To detect salivary gland lesions.	FNA	Se : >90% Sp : >90%	a) Interrelated flat sheets and nuclei of duct cells arranged uniform, small shaped consisting of dense stout cytoplasm and uniform nuclei. b) Sparsely cellular with round clusters of serous cells.	a) Polygonal cells b) Abundant granular or vacuolated cytoplasm. c) Presence of prominent nucleoli. d) Background necrosis prominent. (See Fig.6)	a) Malignancies cannot be distinguished
15	Soft tissue masses	Screening tool for soft tissue masses	FNA	Se :90% Sp :54%-98% Acc : >90% F P : 0%-3% F N : 2%-13%	a) Small bland nuclei without atypia. b) Unvacuolated nuclei of uniform size.	a) Hypercellular b) Pleomorphism. c) Mitoses and background necrosis present	a) Intermediatory conditions between benign and malignant are tough to determine.
16	Thyroid cytology	To indicate presence of thyroid nodule	FNA	F P : 1% - 3% F N : <1%	a) Sparsely cellular. b) uniform and evenly spaced follicular cells. c) Coarse chromatin pattern. (See Fig.4.1.a)	a) Enlarged nucleus. b) Nucleus oval or elongated in shape with irregular contours, pale in color. Overlapped nuclei. (See Fig.4.1.b)	a) Sampling error
17	Urine bladder washing	To detect bladder cancer	Depends on urine specimen type : Voided, catheterized bladder washing, ilioal loop	Catheterized urine : Sp :95% -100% Se : 75% F P : 1.3%-15%	a) Presence of crystals b) Enlarged nucleus with prominent nucleolus. c) Coarse, vacuolated cytoplasm. (See Fig.5.1.a)	a) Round dark nuclei b) Background necrosis (See Fig.5.1.b)	a) Distinguishing characteristics between high grade lesions from low grade lesions are ambiguous.

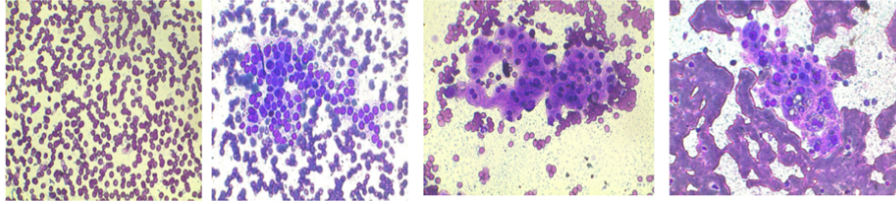


Figure 4: Sample images of (i)Thyroid cytology(40X magnification) (a) Benign case, (b) Malignant case and (ii)Liver cytology(40X magnification) (a) Benign case, (b) Malignant case

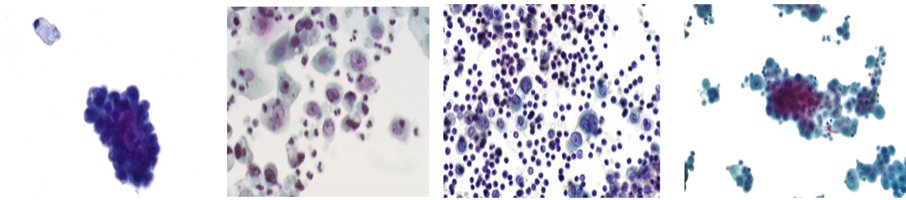


Figure 5: Sample images of (i)Urine cytology (a)Benign case[115](40X magnification), (b) Urothelial carcinoma[15](40X magnification) and (ii)Pleural fluid cytology (a) Benign mesothelial cells (pleural fluid) [114](40X magnification), (b) Mesothelioma cytology [111](40X magnification)

4.1 Cervical cell cytology

According to the latest report by WHO [179], cervical cancer ranks fourth among cancers frequently found in women. It originates from woman's cervix and invades other parts of the body later. In earlier stages, there is hardly any symptom. In advanced stage, symptoms like abdominal pain, vaginal bleeding, abnormal watery discharge, bleeding after menopause etc. are observed. The origin of cervical cancer is human papilloma virus (HPV) that causes abnormal growth of cells of cervix(cervical dysplasia). There are mainly four types of cervical cancer such as:

a) **Squamous cell carcinomas:** It is the most commonly known form of malignant tumor of cervix and accounts for nearly 85% of the overall cervical cancer in women of age between 40 and 55 years. These cells are lying on the outer surface of the cervix and are thin and flat shaped. b) **Adenocarcinomas:** It originates in glandular cells that line the upper area of cervix and accounts to 10% of the overall cases of cervical cancer. Mean age of patients is 55 years. c) **Adenosquamous carcinomas:** It consists of both the squamous and glandular cells and accounts for nearly 2-3% of cervical cancers. d) **Small cell carcinomas :** Generally very aggressive in nature and rarely found (2-3%) which corresponds to stage IV of the cancer. Its cytomorphology exhibits a nesting pattern and often arranged in sheets.

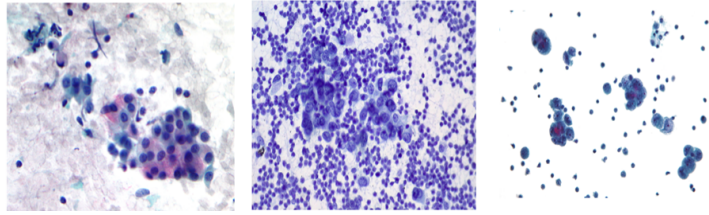


Figure 6: Sample images of (i)Salivary gland cytology(Mucoepidermoid carcinoma)[112](40X magnification), (ii) Lymph nodes(Adenocarcinoma in Hilar Lymph Node)[172](40X magnification),(iii) Ovarian lesions cytology(Serous carcinoma cytology)[113](40X magnification)

4.1.1 Modalities of cervical specimen collection

Cervical smears are normally obtained using a spatula and brush and at so falls under brush cytology. A plastic spatula is rotated 360 degrees and the samples are exfoliated from ectocervix and endocervix. The sample is smeared on one half of the slide. The slide is then spray fixed immediately to avoid any air drying artifact to prevent distortion of cells. This technique is known as Papanicolaou test or Pap smear test.

4.1.2 Differential characteristics associated with cytomorphology of malignant cells

Malignant cells of cervix are generally found in clusters of small cells with scant cytoplasm as shown in Fig.7. Nuclear hyperchromasia and nuclear membrane irregularity are also commonly observed in malignant cells. These characteristics are crucial in categorizing the specimen into benign and malignant using both manual and automated analysis.

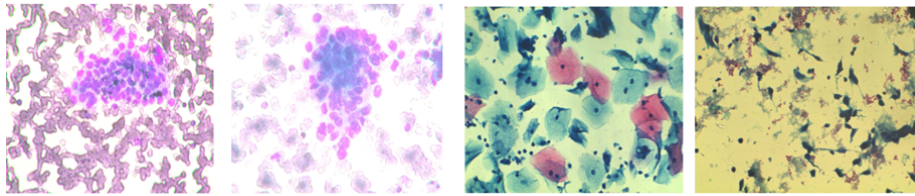


Figure 7: Sample images of (i) Breast cytology(40X magnification) (a)Benign case(b)Malignant case and (ii)Cervical Cytology(40X magnification)(a)Benign case(b) Malignant case

4.1.3 *Significant works on automated screening of cervical cell*

Malignant nuclei differ significantly from benign nuclei in shape, size and textural pattern. Thus, nuclei have sufficient diagnostic information embedded in it and hence possess enormous discriminative power to classify various stages of cancer [7]. Thus, accurate segmentation of nuclei is of prime importance for the researchers, working on cytological images. We categorize the review of research works based on two approaches as stated previously: i) Segmentation based approach, ii) Segmentation free approach.

i) Segmentation Based Approach

A good segmentation algorithm is the necessary footstep for extracting nuclei discriminating features and hence classify the image based on the extracted features. Various segmentation approaches to classify cervical cytology images are discussed in this section.

Thresholding based: This is one of the most common and simplest techniques for extraction of foreground pixels. Walker [174] cited some morphological operations based on octagonal structuring element. Coarse segmentation of gray-scale images was done using Global thresholding. A closing morphological transform having a structural element of size smaller than the smallest nucleus removed the cytoplasm region. The nuclear heterogeneity was adjusted by an opening operator of that size. Still, it could not be fully automated. Zhang et al. [203] proposed adaptive thresholding method where the RGB image was converted into HSV image. V-channel was extracted for histogram stretching. In the pre-processing stage median filtering was done to remove the noise in the image. Adaptive thresholding well mitigated the issue of non-uniform illumination. But choosing the size of the neighborhood and an offset value ($\theta = 15$) in an optimized way, was the major hurdle to segment clustered nuclei. Therefore, in order to segment overlapped nuclei, concave point based method was applied with significant reduction in computational time.

Region based: Region based segmentation technique seeks to divide the image into sub images based on some homogeneity conditions. Mat-Isa et al. [101] designed a combination of moving k-Means algorithm and modified seed based region growing (MSBRG) algorithm to extract the region of interest (ROI) from the image. Each pixel was assigned to the nearest cluster point using a suitable threshold by Moving k-Means algorithm. Based on calculated thresholds and dynamic seed points MSBRG was used to delineate the nucleus and cytoplasm edges. Thin prep images are generally afflicted by various factors like low contrast, haziness, noise resulting in increased false negative cases. Mustafa et al. [109] proposed to enhance the contrast of thin prep images via three different methods viz. linear contrast, nonlinear bright and dark contrast. An MSBRG method was used to segment nuclei. The later two contrast enhancement methods enhanced the images by increasing the contrast of the bright areas and dark areas respectively. In another work, Mat-Isa et al. [102] proposed a CAD based system based on region-growing-based features extraction (RGBFE) technique. It comprised of a) An automatic feature extraction system to extract features like nucleus size, grey level intensity of nucleus, size of the cytoplasm and

Table 2: A brief overview of different works in Cervical cancer cytology identification where Accuracy (Acc), Jaccard Index(JI), Specificity (Sp), Sensitivity(Se) and Dice Similarity Coefficient (DSC) are represented in their corresponding bucket given in abbreviated form.

SL#	Author's name	Name/Source(N/S) and Number of samples(Size) in the Dataset	Method for segmentation image	Features of Nucleus and cytoplasm and classifier used	Quantitative results and Findings (Accuracy (Acc), Jaccard Index(JI), Specificity (Sp), Sensitivity(Se), Dice Similarity Coefficient (DSC))
1	Holmquist et al. (1978)[57]	N/S: University Hospital (B.S.), Uppsala, Sweden Size: 720 single cells of eight different categories (4 normal and 4 malignant)	Nuclei of single cells are segmented using dual wavelength method	Features: Density, shape, and texture-oriented features of nuclei. Classifier: LDA based binary classifier.	Acc: 97% in binary class Findings: Algorithm does not deal with superimposed cells.
2	Mat-Isa et al. (2008) [102]	N/S: Kota Bharu Hospital and Universiti Sains Malaysia Hospital, Malaysia Size: 550 images of three class	Modified seed-based region-growing algorithm	Features: Nucleus size, nucleus grey level, cytoplasm size and cytoplasm grey level, Region-growing based features extraction . Classifier: H^2 MLP.	Acc: 97.5 Sp: 100 Se: 96.67 Findings: Algorithm does not deal with superimposed cells.
3	Chankong et al. (2009) [21]	N/S: ERUDIT Dataset. Size: 276 single cell images. 138 normal cells (63 superficial cells, 75 intermediate cells), and 138 abnormal cells (34 light dysplastic cells, 34 moderate dysplastic cells, 35 severe dysplastic cells and 35 carcinoma in situ cells).	Fourier Transform	Features: Mean, variance, and entropy. Classifier: Bayesian classifier, linear discriminant analysis (LDA), KNN, ANN, and SVM	Acc: 92.65 (Highest SVM) False positives: 7.35% False negatives: 7.35% Findings: Experimented with single cells. Overlapping cells which is the practical scenario are not considered.
4	Li et al. 2012 [88]	N/S: Herlev dataset, Size: 917 images	Spatial K-means clustering followed by RGVF Snake incorporating a stack-based refinement using edge map	Classifier: interpretation, visual	Zijdenbos similarity index: 94% Findings: only segmentation of isolated cells. Overlapping of cells not considered.
5	Genctav et al.[45]	Herlev data set, Size:917 images of Pap cell Hacettepe data set. Size:82 Pap test images	Non-parametric hierarchical segmentation.	Features: 12 features of cells including spectral and shape. Classifier: spectral, shape and gradient information of nucleus for classification.	Correct classification rate is 96 % Findings: Parameter free segmentation. Clusters of overlapped regions not addressed.
6	Zhang et al. (2014) [204]	N/S: Shenzhen Sixth People's Hospital Huaizhong University of Science and Technology Union Shenzhen Hospital, Shenzhen, China, 2010. Size: 51 images (21 slides).	Local graph cut and global graph cut to delineate cytoplasm and nucleus. Concave point based algorithms to segment overlapping nucleus.	Features: nucleus and cytoplasm texture, shape and size. Classifier: Visual interpretation(only segmentation is reported)	Acc: 93% for segmentation purpose Findings: Touching nuclei are segmented. Poor contrast images are underestimated.
7	Nosrati and Hamarneh (2015) [118]	N/S: ISBI Overlapping Cervical Cytology Image Segmentation Challenge. Size: 135 images (45 images for training and 90 images for testing).	Star shape prior and Voronoi energy term.	Features: (HOG) features are used for training the nucleus to cytoplasm ratio. Classifier: Visual interpretation.	DSC: 0.88 Findings: In multiple overlapped regions the boundary of each cell is little ambiguous. Time to segment each image is 6.6 sec. (approx.).
8	Mariarpatham and Stephen (2015)[99]	N/S: Herlev dataset Size: 917images	Image inversion, binarization, morphological closing with structuring element of size 5 and filling operation.	Features: 24 features including nucleus related, moment, texture etc. Classifiers: SVM and Neural Network .	Acc: 81.85% (best SVM) for seven class problem on 10 fold cross validation. Findings: Dill with only single cell images.
9	Zhang et al. (2017a)[205]	N/S: 1)Herlev dataset 2)HandE stained manual LBC Dataset Size: Herlev dataset(917), HEMLBC dataset(21)	Graph Search based segmentation of nuclei	Assessment based on 5-fold segmentation performance.	On Herlev dataset(for carcinoma having 150 cells) : Precision:93%±0.08, Recall:91%±0.13 On HEMLBC dataset(for carcinoma having 150 cells) : Precision:91%± 0.04, Recall:96± 0.04% Findings: Global optimal solution achieved. Overlapped cells are not addressed, also accuracy is highly dependent on initial segmentation .
10	Zhang et al. (2017b)[206]	N/S: 1)Herlev dataset 2)HandE stained manual LBC Dataset Size: Herlev dataset(917), HEMLBC dataset(21)	No segmentation	Used previously trained CNN (trained on ImageNet) 5 convolution layer and 3 forward connection layer.	On Herlev: Acc: 98.3%, Sp: 98.3% Se: 98.2% On HEMLBC: Acc: 98.6%, Sp: 99.0 % Se: 98.3% Findings: Multiple and overlapper cells not considered. Misclassification rate is higher.

grey level intensity of cytoplasm using region growing method and b) A diagnostic system was designed using hierarchical hybrid multilayered perceptron (HHMLP). An accuracy of 97.50% was reported on their dataset consisting of 550 reported cases "(211 normal, 143 Low-grade Squamous Intra-epithelial Lesion (LSIL) and 196 High-grade Squamous Intra-epithelial Neoplasia (HSIL) cases)".

Contour based: Active contour or snake model (ACM) seek to segment the image using the initial contour information. But ACM fails for poor quality images and is also sensitive to the detection of initial contour. Snake model is one of the popularly used contour models for segmentation nuclei from cytoplasm and background. Yang-Mao et al. [196] proposed an edge enhancement nucleus and cytoplasm contour detector (EENCC) algorithm involving five steps: trim-meaning filter, bi-group enhancer, computation of gradient, MVD (Maximum Valued Difference), and contour extraction. EENCC performed better than snake models with least relative distance error (RDE) of 0.288. Harand et al. [56] adopted a geometric active contour algorithm followed by Sauvola thresholding and FIFO queue structure to identify boundary of nucleus within each cell. The contour obtained in low resolution is taken as the input. It showed better results compared to the EENCC detector. Guan et al. [51] attempted to segment partially overlapping cervical cells in high resolution images. A dynamic sparse contour algorithm was used to detect weak contour points in the nucleus. Then GVF (Gradient Vector Flow) snake model was applied to find out the exact contour of cell. However, the method could not handle more than two overlapped cells. Moreover, its performance degrades with low resolution images.

Deformable Contour model based: The Active Contour Model (ACM) pioneered by Xu et al.[192] is extensively used to extract the objects with irregular boundaries, contour with noisy interior and contour with small breaches. Tsai et al.[168] developed a three-staged cytoplasm and Nucleus Contour (CNC) detection technique for segmentation of nuclei and cytoplasm. A bi-group enhancer, in first stage was used to sharpen the contour of nucleus by increasing the contrast between nucleus and cytoplasm regions. Cytoplasm contour detection using K-means clustering was applied in second stage. In the last stage, contour of the nucleus was detected by applying Maximal Color Difference (MCD) method. But a prior denoising by means of median filter is a prerequisite to acquire a satisfactory result. Li et al. [88] used priory spatial K-means clustering algorithm to segment the image into background, nucleus, and cytoplasm for free lying cells. A radiating gradient vector flow (RGVF) based snake algorithm was applied to get fine segmentation. RGVF involved a stack-based refinement and an edge map based technique to identify the unclear and incomplete edges, but eventually failed to segment overlapping cells. Furthermore, the performance was highly dependent on accuracy of initial contour extraction. Bergmeir et al.[8] proposed a web-based software module with a prior noise removal technique using mean-shift and a median filtering. A randomized Hough transform was used to detect candidate nucleus that was segmented by level set methods. The experiment was done on 207 cervical images with an F-measure of 96.15%

and true positive rate of 95.63%. But in the proposed system ROI was selected manually by cytotechnologists. Lu et al. [95] proposed the segmentation of non-overlapped nuclei using MSER (Maximally Stable Extremal Regions) technique where cell clumps were taken as input. To segment overlapped cells they used joint level set optimization. But, considering the shape of the nucleus as ellipse to model the segmentation problem, the accuracy level was compromised to some extent. But the cytoplasm boundary for low contrast images could not be properly delineated also the system should be validated with true dataset. To overcome this problem, Nosrati et al.[118] assumed a star shape prior instead of ellipse, for better approximation of the nuclei shape, which was encoded in a vibrational framework having directional derivatives. To address overlapped cells, they included Voronoi energy term, which bounded the amount of overlapping in adjacent cytoplasm.

Texture based: Texture is an intrinsic property of an image which can be used to extract useful contents from an image. So, researches are motivated towards texture analysis for classification of pap-smear images. Among seven different sets of texture feature, LBP(Local Binary Pattern) and GLCM(Gray Level Co-Occurrence Matrix) were used for classifying pap smear cells of Herlev dataset, a standard freely available Pap Smear dataset, consisting of 917 samples, into seven output classes using SVM(Support Vector Machine) and NN(Neural Network) classifier [99].

Graph based: A graph-cut approach was advised by Zhang et al. [202] to segment cervical cells of manual liquid based cytology. A multi-way Graph-cut approach was used to segment cytoplasm. This technique grossly classified the image into background (with lowest mean intensity) and cytoplasm, nuclei, inflammatory cells and debris. For precise nuclei segmentation, they used graph-cut approach adaptively and locally. To split touching nuclei, two concave point based algorithms were combined. But the system could not detect cytoplasm boundary. Also, nucleus having poor contrast could not be delineated completely. A graph search based cervical cell segmentation methodology was presented by Zhang et al. [205]. Initially they defined the center point and the size of the nucleus. For segmentation of nucleus boundary they used graph search based method where the shape information was plotted as a graph (Cartesian to polar plot) by designing a cost function based on edge term and region term. Optimal path of the graph was dictated by dynamic programming. To obtain closed contour of nucleus in Cartesian coordinate system, reverse mapping was done. This work was tested on two standard datasets: Herlev and HEMLBC dataset. This method showed fast optimization process but the accuracy depends greatly on closeness of initially detected nucleus center point to the actual one.

Clustering based: Kim et al.[79] suggested a Fuzzy C-Means (FCM) based segmentation method on uterine cervical images in HSI colour space. A patch based FCM clustering technique was proposed by Chankong et al.[23] for segmentation of nucleus, cytoplasm and background. Six nuclei features were extracted to classify cervical cells using five classifiers: Bayesian classifier, Linear discriminant analysis (LDA), KNN, SVM, ANN. They experimented on ERU-

DIT Pap smear dataset, LCH Dataset and Herlev dataset. For a two-class problem, ANN gave best recognition accuracy of 97.83%, 97.00% and 99.27% on three datasets respectively. Zhao et al.[207] applied Markov Random Field (MRF)based segmentation model after getting super pixels from cervical images. The gap search algorithm with reduced time complexity used further based on the labelling of nucleus, cytoplasm and other components of the cell.

Deep Learning based: Deep learning based framework is one of the latest trends in many applications and being extensively used in segmentation of cytology images. Song et al.[151] developed a CNN (Convolutional Neural Network) based segmentation framework combined with a superpixel based technique for segmentation of nucleus. The gaussian noise generated during image acquisition process was removed by trimmed meaning filter. The cytoplasmic mask was extracted by high-dimensional Otsu thresholding method. A superpixel based SLIC (Simple Linear Iterative Clustering) segmentation was applied on masked images. To extract features of superpixels, CNN was applied. Coarse nuclei segmentation was done to reduce overlapping of inflammatory cells. A new template was constructed to improve segmentation. The nuclei region detection accuracy was obtained as 94.50 % using CNN. Liu et al.[92] proposed an automated image segmentation method by Mask-RCNN (Mask- Regional Convolutional Neural Network) and LFCCRF (Local Fully Connected Conditional Random Field).The Mask-RCNN, which was constructed by residual neural network based FPN (Feature Pyramid Network), was modified depending on cervical nuclei images. The pyramid feature maps were extracted by Mask-RCNN through pixel level information of the nuclei. The Mask-RCNN based coarse segmentation of nuclei were performed and ROI was obtained by increasing the bounding box. For further refinement LFCCRF was used with intensity and position information of all pixels in that region. Phoulady et al.[126] proposed a CNN based nucleus detection technique using iterative thresholding method to find the seed point of nuclei. CNN was trained with the patches of nuclei. This approach showed a precision, recall and F-score of 0.861,0.895 and 0.878 respectively on the cervical cytology dataset 'CERVIX93'.

Other approaches: [163] studied the influence of ICM (Intersecting Cortical Model)where the parameters were optimized using Particle Swarm Optimization (PSO). Several other algorithms like Otsu thresholding, Expectation Maximization, Region Growing and Fuzzy C-Means clustering were studied in the experiment with 250 cervical images. ICM was reported with a highest PSNR of 62.946 dB. An unsupervised segmentation of Pap smear cells was proposed by Happy et al.[54] in two stages. The cells were divided based on homogeneity and circularity using multi-scale hierarchical segmentation. The nucleus and cytoplasm was classified using a binary classifier. They segmented overlapping nuclei using extended depth of field (EDF) images from different focal planes with various degrees of overlap. Modified Otsu using class prior probability was used to select suitable threshold to segment nucleus. The work was validated on ISBI 2015 challenge dataset with a DICE score of 0.86 and a TP rate 0.88. Lakshmi et al.[5] applied Haar wavelet to nullify the effect of

uneven staining in the pap-smear images followed by adaptive median filter to remove noise. ICM and cuckoo search algorithm jointly used to segment the nucleus in an optimized way. However the initial parameters were chosen manually. Ilyasu et al. [64] investigated a hybrid approach of feature set selection. They combined quantum particle swarm optimization (QPSO) algorithm with Fuzzy k- nearest neighbours (Fuzzy KNN) algorithm to scale down 17 features relating color, geometry and texture of nucleus to 7 features. Selected features prior to hybrid approach based classification showed greater classification accuracy compared to All-feature-Based approach (no feature selection). A cellular neural network based cervical cancer detection method using customized template was advocated by Abdullah et al. [1]. Three templates were used such as 1) modified blue channel extraction template for identification of nuclei from the cell 2) modified contrast enhancement template for identifying nuclei with finer details from modified image 3) modified hollow concave template for removing noisy background. A recognition accuracy of 90.77% and 85.54% for cancerous and non-cancerous cells respectively.

ii) Segmentation Free Approach: Recently with the onset of deep learning based techniques, deep convolutional networks can be applied directly to classify pap-smear cells without requiring prior segmentation. Most of the researchers used transfer learning or fusion of different CNNs in their works. In the paper [10], VGG net-16, a common CNN architecture for feature extraction, was used for classification using Least Square Support Vector. Zhang et al.[206] introduced DeepPap, a CNN architecture using the concept of transfer learning. A pre-train architecture of image net for pap smear was used for image classification. They observed a recognition accuracy of 98.3% and 98.6% on Herlev and HEMLBC dataset respectively using five fold cross validation. Hyeon et al. [63] used VGG-16 net, a pre-trained CNN architecture for feature extraction. The extracted features were used to classify using SVM. 71,344 Pap smear images were collected from Seegene Medical Foundation to form a dataset consisting of 8,373 samples of normal class and 8,373 samples of cancerous or abnormal class. A recognition accuracy of 78% and 20% was observed on the test samples of the dataset. Some major segmentation techniques used in cervical cytology are shown in Table 3.

Classification:

After segmentation of nucleus of Pap smear images, different nuclei centric features are extracted to classify pap smear images into two classes Benign and Malignant. Malignant or cancerous are further classified into different categories based on their stage. A single classifier or combination or ensemble of different classifiers are used. Among different classifiers binary classification method [57], Artificial Neural Network (ANN) and its modifications [103, 102, 23] Support vector machine (SVM) [201, 121], Fuzzy C Means (FCM) [79, 127] etc. are popularly used. Deep learning techniques [206, 157] etc. are recently introduced for classification of cervical cells.

Binary Classification: Holmquist et al.[57] developed a binary classification framework on Linear Discriminant Analysis (LDA) to distinguish cervical images using density, shape, and texture-oriented features of nuclei.

Hierarchical approach: Mehdi et al.[103] introduced hierarchical approach to classify images into mild, moderate and severe cells using ANN with back propagation algorithm. Ramli et al. [135] approached with a non-linear hybrid multi-layered perception(HMLP) model using least square algorithm to classify cervical cells into normal and low-grade squamous epithelium. Mat-Isa et al.[102] also recommended an HMLP network to classify single cell images using different feature informations such as nucleus size, nucleus grey level, cytoplasm size and cytoplasm grey level etc.

Support Vector Machine(SVM): Zhang et al.[201] used SVM to detect cancerous cells from multispectral pap smear images. During feature selection Sequential Backward Selection (SBS) was applied. They obtained better performance after using SVM based screening with smaller number of features.Monteagudo et al.[121] proposed a combination of SVM and waterfall algorithm also classify cancerous and normal specimens.

Fuzzy C-Means(FCM): Kim et al.[79] suggested FCM based nucleus recognition techniques to distinguish normal and abnormal cells in HSI images. Different nucleus specific information such as circumference of nucleus, different ratios from nucleus and cytoplasm, degree of roundness, etc. [127] were used to detect true nuclei points using different extrema points in the images. FCM was preferred over SVM for classifying the normal and abnormal cells due to limited data set.

Convolutional Neural Network: Song et al.[150] proposed multi-scale convolutional network (MSCN) and graph based partitioning technique to segment touching nuclei. MSCN was used for initial segmentation of nuclei extracting multiscale feature vectors. It was fine segmented using graph partitioning to get accurate result. When compared to raw pixel segmentation, superpixel based segmentation of cytoplasm and nucleus gave an improved accuracy of 5.06% and 2.06% respectively. Braz et al.[14] proposed another CNN based technique for detection of nucleus in pap smear images. Gautam et al. [44] proposed a cell nuclei detection technique using patch based CNN. The segmented nuclei were classified using transfer learning on AlexNet. They also proposed a decision tree based technique. A recognition accuracy of 99.3% in two- class problem and 93.75% on a seven class problem was reported on the same dataset. Wu et al.[188] proposed AlexNet based Deep convolution neural network model which was trained using three fold cross validation.For data augmentation flipping and rotation techniques were done. Training and testing process was done on both original RGB and augmented image datasets. Each dataset consisted of keratinizing squamous, non-keratinizing squamous and basaloid squamous. In different groups of datasets they reported recognition accuracy of 93.33% and 89.48% for original and augmented images respectively. Meiquan et al. [104] proposed an automated cell detection technique using a faster R-CNN method. Using Resnet-101 the features were extracted. In testing phase, the data were enhanced by rotating the patches at 90°, 180°, 270°. A recognition accuracy of 0.91, 0.78, 0.70 was reported on validation set, two class and four class problem respectively.

4.2 BREAST cancer cytology

Breast cancer, though, mostly prevalent among women all over the world, occurrences found in men are rare (cases found are mostly invasive in nature). In women, the incidence and deaths due to breast cancer is the highest posing a global burden irrespective of all levels of modernization. Breast cancers originate either in the lobules, or in the ducts that connect the lobules to the nipple. Breast cancer does not show symptoms when the tumor is small enough to be felt and can be easily cured. It starts with a painless lump and slowly progresses with other symptoms like pain, breast heaviness, swelling, redness of the skin. Nipple abnormalities such as spontaneous watery or bloody discharge or retraction are also common. Samples of cytology images of breast are shown in Fig.7. Breast cancer is generally categorized into i) Carcinoma In Situ, ii) Invasive.

i)In Situ: Here instances of abnormal cells that are found locally and have not spread to nearby cells. These are mainly of two types: ductal carcinoma in-situ (DCIS) and lobular carcinoma in situ (LCIS)or lobular neoplasia.

Table 3: A brief overview of different works in Breast cancer cytology identification where Accuracy (Acc), Jaccard Index(JI), Specificity (Sp), Sensitivity(Se) and Dice Similarity Coefficient (DSC) are represented in their corresponding bucket given in abbreviated form.

SL #	Author's name	Name/Source(N/S) and Number of samples (Size) in the Dataset	Method for image segmentation	Features and classifier used	Quantitative results and Findings
1	Wolberg et al. (1993)[184]	N/S: University of Wisconsin Clinical Sciences Center Highland Avenue Madison, Wisconsin, USA. Size: 119 images. 68 benign 51 malignant.	Manual segmentation followed by active contour detection.	Features: size, perimeter, area, compactness, radial variance, concavity, texture, size uniformity, worst size, worst shape. Classifier: MSM-Tree.	Acc: 90% Findings: Manual segmentation of nucleus boundary is cumbersome and time consuming
2	Weyn et al. (1998)[178]	N/S: Antwerp University Hospital, Wilrijk, Belgium. Size: 83 images. 20 benign, 63 malignant	Segmentation not done	Features: Wavelet, Denisometric, co-occurrence, morphometric features. Classifier: KNN	Acc: 76.1% Findings: Operator supervision is required and also false negatives present.
3	Street (2000a)[153]	N/S: University of Wisconsin Hospitals and Clinics beginning in 1984. Size: 569 images. 357 benign, 212 malignant.	Generalized Hough transform	Features: 30 numbers of nuclear morphometric features. Classifier: MSM-Tree	Acc: 97.5% Se: 96.7% Sp: 98.0% Findings: Accurate closed boundaries, false findings persist, overlapped cells not taken care of. Not fully remote, requires end user intervention
4	Isa et al. (2007)[66]	N/S: Penang General Hospital and Hospital Universiti Malaysia, Kelantan, Malaysia. Size: 1300 images in 4 categories.	Segmentation not done	Features: 13 features of different cellular and nuclei properties extracted. Classifier: Hybrid MLP (800 training and 500 test cases)	Acc:100% Findings: Intelligent system, where staging of cancer can be determined.
5	Jelen et al. (2008b)[71]	N/S: Medical University of Wroclaw, Poland. Size: 66 (intermediate malignancy), 44(high malignancy)	Level set method	Features: area, perimeter, convexity, eccentricity and one texture feature. Classifier:MLP, Self-organizing maps (SOM), PCA, SVM.	Acc: Maximum 94.24%with SVM. Findings: Degree of malignancy can be determined
6	Malek et al. (2009)[97]	N/S: Farhat Hached Hospital, Sousse,Tunisia. Size: 200 images in test data set. 120 benign,80 malignant.	GVF Snake	Features: wavelet based texture features. Classifier: Fuzzy C-means	Acc: 95% Findings: Developed FPGA based hardware system of software counterpart
7	Kowal et al. (2011)[82]	N/S: Regional Hospital in Zielona Gora, Poland. Size: 500 images from 50 patients (10 images/patient). 25 benign, 25 malignant.	Adaptive thresholding and Gaussian mixture model based segmentation.	Features: Different Nuclei and cytoplasm centric features. Classifier(s): KNN, Naive Bayes classifier, DecisionTrees, Ensemble Classifier.	(Maximum using KNN) Acc: 98% Findings: Incorrect nuclei clusters are generated for lower no. of pixels. No standard dataset.
8	Filipezuk et al. (2013a)[40]	N/S: Regional Hospital in Zielona Gora, Poland. Size: 737 images from 67 patients (cases)	Circular Hough transform	Features: Nuclei and cytoplasm centric features with different intensities of RGB images, Correlation, Energy, Homogeneity etc. Classifier(s): KNN, Naive Bayes, Decision Tree, SVM	(Maximum using SVM) Acc: 98.51% Findings: False circles are eliminated. No standard dataset.
9	Issac et al. (2013)[68]	N/S: Pathology lab of Regional Cancer Center, Thiruvananthapuram. Size: 334 (benign proliferative 311(infiltrating)	K-means clustering technique in LAB color space.	Features: Textures and Nuclei centric features extraction after using complex Daubechies Wavelet Transform. Classifier: KNN	Acc: 93.9% Se: 92.2% Sp: 95.9% Findings: Complex wavelet performed better than real wavelet. More morphometric features can improve results.
10	George et al. (2014)[46]	N/S: Ain shams University Hospitals,Egypt Size: 92 images. 45 benign, 47 malignant having 11502 cell nuclei.	Marker controlled watershed segmentation	Features: 12 statistical features, 10 texture features and 2 intensity based features. Classifier(s): SVM, LVQ, PNN, MLP	Using PNN (max) Se: 96.32% Sp: 94.57% Findings: Developed fully automated remote system. Grading of malignancy not done.
11	Garud et al. (2017)[43]	N/S: Sub-divisional Hospital, Kharagpur, and Midnapur Medical College and Hospital, Midnapur, India. Size: 37 samples,24 benign, 13 malignant.	Manually selected ROI	Features/classifier: Images are subdivided randomly to fit in GoogLeNet architecture and performances are reported both ROI level and sample level.	Acc: ROI: 80.76%. Samples: 89.71%. Findings: Nuclei centric feature based approach perform better than GoogLeNet.
12	Zejmo et al. (2017)[199]	N/S: Regional Hospital in Zielona Gora, Poland. Size: 50 patients 25 benign, 25 malignant cases.		Features: 697 patches/ image were extracted. Classifier: CNN models AlexNet and GoogLeNet. Used randomly selected patches of 256 × 256 from large sized images.	Acc: 80% and 83% on the patches using AlexNet and GoogLeNet. Findings: GoogLeNet perform better than AlexNet.

- Ductal carcinoma in situ. In this condition abnormal cells takes place of the normal epithelial cells which surround the breast ducts. It does not necessarily progress towards invasive stage.
- Lobular carcinoma in situ. Under ths situation, the growth of abnormal cells extends to some lobules of the breast and often progresses to invasive cancer.

ii) Invasive: It has two subtypes: a) Regional stage: Abnormal cells have spread to neighbouring tissues and nearby lymph nodes (stage II or III cancers), . b) Distant stage: A condition in which abnormal cells have metastasized to different organs or lymph nodes above collarbone (stage IIIc and stage IV cancers).

4.2.1 *Modalities of breast specimen collection*

Patients suffering from breast cancer disease are curable if detected at an early stage. Very often symptoms do not develop at early stages as they do develop when cancer has already reached an invasive stage (generally correspond to stage III or IIIc and stage IV cancers). So, a routine screening examination is always encouraged, before symptoms actually start to divulge. This can be done by simply perceiving a lump. Two modalities of specimen collection are normally practiced for breast cancer detection and diagnosis: a) Discharge cytology b) FNAC. FNAC is used to evaluate palpable and non-palpable breast lesions. Fine-needle or wider core needle or a surgical incision picks requisite amount of mass from several points of the site required for diagnosis. Then, microscopic analysis of breast tissue is done by an expert to determine the extent of percolation of abnormal tissues. Nipple discharge cytology is usually performed to very few patients who are generally asymptotic.

4.2.2 *Differential characteristics associated with cytomorphology of malignant cells*

- Large, angulated, eccentric, pleomorphic nuclei with irregular boundaries.
- Irregular spacing between adjacent nuclei.
- Background debris in large proportion.

4.2.3 *Significant works on automated screening of breast cell*

Researchers are attempting to evolve image processing techniques [153, 116] since three decades to commensurate for the complex nature of breast cytological images embedded with various degradations. We proceed to discuss the works of breast cytology in a similar fashion: a) Segmentation based approach b) Segmentation free approach. It is worthy to mention, preprocessing techniques such as color conversion, image normalization, contrast enhancement etc. [137] are considered essential prior to applying segmentation techniques. So image enhancement techniques are often omitted during discussions without the loss

of generality.

i) Segmentation based approach

Nuclei are segmented first and then different nucleus specific features are extracted to classify benign and malignant cells. But grabbing suitable image segmentation algorithms fit for the purpose is a challenge to the research community. Difficulty in segmentation arises mainly due to variable structural and textural pattern of the nucleus along with various inherent noise of the specimen. This becomes more complicated with the presence of overlapped nucleus. In following few paragraphs, we highlight some important and popularly used segmentation techniques with the aim to develop knowledge of the existing works under each subheading.

Contour based: Active contours since its introduction by Kass et al. [74] in the year 1988 has been extensively studied in subsequent studies [186, 6]. Wolberg et al. [184] used manual segmentation to define nucleus boundary initially. For precise nucleus contour detection, they invoked snake model that can be confined to the nucleus region using proper energy function. 11 different features of isolated nuclei like size, perimeter, area, compactness, radial variance, concavity, texture etc. were extracted from nucleus. Based on that, they classified the data using MSM (Multisurface Method)-Tree classifier. In their following work Wolberg et al. [185], reported an accuracy of 97% with a slight modification of their previous work, with maximum result obtained as 97.5% for non-overlapped nuclei segmentation on their test dataset. Usage of Compact Hough transform for nuclei segmentation [107] and generalized hough transform with deformable models [86] are found in literature. Bamford et al. [6] prescribed an improved snake model to overcome initialization problem of conventional snake. Street et al. [153] used Hough transform to point out circle like structures followed by active contouring technique. They proposed an automatic diagnostic and prognosis system "Xcyt" [153] for screening of breast cancer. Hough transform was also adopted by Hrebien et al. [60] followed by an automatic nuclei localization method based on (1+1) search strategy. To segment the nuclei, a combination of active contour model, watershed and grow-cut algorithm was applied. But the technique was not fruitful for overlapping nuclei. Also, false circles were created which was not resolved.

Texture based approach: Wavelet based decomposition has proved to be a powerful tool in analyzing texture or chromatin pattern of nucleus [178, 69, 156]. Weyn et al. [178] used wavelet as chromatin pattern descriptor for semi-automated diagnosis and grading of breast tumor. However, determination of tumor stage is hindered by increased false negative cases. Various other works are registered using DWT as a tool [69, 156] for breast cancer detection. [116] investigated the effect of Log-Gabor wavelet filter on HSV color space. Color wavelet features were deducted on extracted features and compared the relative performances of classifiers viz. SVM, Naïve Bayes and ANN. Highest accuracy accorded by SVM as 98.3% with sensitivity and specificity of 98% and 98.6% respectively. Since DWT lacks phase information, complex wavelet transform was grabbed in follow up studies [20]. In [68], Niwas et al. analyzed nuclear chromatin pattern using complex Daubechis Wavelets. Wavelet co-occurrence

matrix were used to calculate statistical features like cluster shade and prominence, contrast, entropy, energy, local homogeneity and maximum probability K-NN with standard Euclidean distance was used to classify the images.

Region based: Marker controlled watershed segmentation was studied by Yang et al. [195]. Hrebien et al. [60] proposed nucleus segmentation technique using watershed, Active contour and Cellular automata Grow cut techniques. They reported a segmentation accuracy of 68.74% but taking an average of 4–5 minutes to segment an image. Also, fake circles that were created during the nuclei detection stage using Hough Transform could not be removed completely. George et al. [46] suggested a fully automatic method for nuclei segmentation of breast FNAC images. They extracted Y component of YCbCr color space for grey level conversion followed by Hough transform to detect circular shaped structures. To eliminate the generated false circles, Otsu’s thresholding method was applied. To detect the nuclei boundaries by avoiding over-segmentation, Marker controlled watershed transform was used after that. Twelve features were extracted for classification using MLP, PNN, LVQ, and SVM with 10 fold cross validation.

Clustering based: Clustering based approach was studied in the work of [6] using water-emersion algorithm. Seed based growing and moving k-means was propounded by Isa et al. [66] to determine the stages of cancer. Na et al. [110] used anisotropic diffusion to determine the malignancy. Filipczuk et al. [41] approached with three level binarization algorithm by extracting the luminance component using $L=0.2126R+0.7152G+0.0722B$. Initial segmentation was done using adaptive thresholding. Second level involves clustering algorithms such as k-means, fuzzy c-means (FCM) and Gaussian mixture models (GMM) to partition the image into nucleus, cytoplasm and background using different color channels as features. In the final level, they combined the two segmented images using an AND operator to give precise definition of the boundaries of the image. But this method suffers from two major limitations. The need for determining optimal parameters and issues associated to unsupervised clustering restricted its use to practical purpose.

Deep Learning based approach: Saikia et al.[139] developed a CNN based deep learning classification framework where images were augmented using techniques like cropping, shearing, rotation, mirroring, skewing , inverting, zooming. In subsequent phases, channel identification, histogram equalization and Otsu’s thresholding were used to segment candidate nuclei . Maximum accuracy of 96.25% was achieved using the GoogLeNet architecture . Kowal et al. [81] proposed a CNN and seeded watershed based breast cytology cell segmentation model. CNN based semantic segmentation model was first applied to differentiate between the nuclei and background. After that, the generated semantic mask was transformed into a nuclei mask to extract the touching and overlapping nuclei. The clustered nuclei were detected by its area and roundness. Nuclei seeds were identified using conditional erosion process. The overlapping nuclei were separated by seeded watershed algorithm. With this approach, 83.4% of benign nuclei were classified using Hausdorff distance.

ii) Segmentation free approach

In this approach, instead of segmenting an image, entire image or randomly selected sub-regions are used for feature extraction and/or classification. Based on various texture features [28] used Das et al. used to classify with the images. With the onset of deep learning based technique in computer vision domain especially in medical images [91, 62] CNN is successfully implemented to detect breast cancers [43, 199]. Garud et al. [43] used GoogLeNet on randomly selected regions from the images during training and testing. An accuracy of 89.71% was reported on the test dataset after voting of classified regions. Žejmo et al. [199] used AlexNet and GoogLeNet by selecting small patches of 256×256 from the large sized images of 200000×100000 pixels. They reported accuracy of 80% and 83% on the two networks respectively. It was noticed that the accuracy observed in the CNN was still lagging behind traditional feature based models. The accuracy can be improved by increasing number of training samples can improve accuracy. Khan et al. [78] proposed a transferlearning based classification technique using VGG net, GoogLeNet, ResNet. For data augmentation translation, color processing, scaling, horizontal or and/or vertical flipping, rotation and noise perturbation techniques were used. Features related to circularity, compactness and roundness were extracted using CNN architectures. The classification accuracy of proposed transfer learning method was obtained as 97.525%. Some notable works on breast cancer cytology are shown in Table 3.

Classification:

Classifiers stand in the final lap of the image analysis system upon which ultimate decision regarding the nature of the specimen (whether malignant or not) is bestowed. The extent to which a classifier can correctly classify images defines the accuracy of the system. With the finest improvement in algorithmic complexity of the well known classifiers, researchers are able to grasp the complex and diverse nature of images. A substantial number of scientific articles are published on a list of classifiers. Among them Multisurface method tree (MSM-T) [183, 153] and KNN classifiers [178, 82, 68] were widely used in the work of breast cytology image classification. Kernel induced methods like SVM, had been studied in the works of [20, 40, 46] to achieve a good accuracy. Artificial neural network based approaches such as MLP [70] and its variant hybrid MLP [66], ensemble of classifiers and Decision trees by Kowal et al. [82] were investigated. A comparative analysis of different classifiers such as SVM, Learning Vector Quantization(LVQ), Probabilistic Neural Network, MLP was done in [46] by George et al. .

Studies are also motivated towards spawning prediction of the recurrence time of the disease. As it requires large amount of statistical data, this is usually treated as a classification problem. Logistic regression was used by Bradley et al. [13] for determining recurrence time of the disease. A standard neural network trained with backpropagation had been proposed by Street et al. [153] to produce predictive breast cancer risk model. These prospective models are still going through several modifications to make the system robust.

4.3 LUNG CANCER

Lungs are a pair of internal organs located on either side of chest and exchange oxygen and carbon di oxide between the air we breathe and the blood. The inhaled air passes through main windpipe known as trachea and conducts air into each lungs via left or right bronchus. Lungs are divided into sections called lobes, two on the left and three on the right. The air passages divide into smaller tubes known as tracheobronchial tree' and connect with tiny air sacs called alveoli. The lungs are protected with a thin tissue membrane known as pleura. Once lung cancer starts to binge to other parts of the body particularly to lymph nodes adrenal glands, liver, brain and bones, it becomes fatal. Causes of lung cancer include smoking, drinking or exposure to various air and water pollutants. Histological subtypes of lung cancer can originate from different locations of the tracheobronchial tree. There are two major types of lung cancer: Non-small cell lung cancer (NSCLC) which accounts for about 85% of it and Small cell lung cancer (SCLC) which is more aggressive than NSCLC tumors, accounts for the rest.

4.3.1 *Modalities of lung specimen collection*

Sputum cytology [136] and FNAC [98] define changes at cellular level to find a definite diagnosis of it and also at the same time they are not expensive. Our present discussion is constricted only to the cytology based diagnosis system. There are three major techniques in cytology to collect specimen from lung nodules: i) Sputum collection ii) Bronchial Techniques iii) FNA Techniques.

i) *Sputum collection*: Sputum samples are usually collected during morning for consecutive 3 days also called 'triple-morning test'. Sputum is collected simply when a person coughs up and so turns out to be a minimal invasive method. The samples are then collected in a Cytolyt container containing 30 ml. fixative and are sent to laboratory. As people under poverty line indulges at a greater rate in filter-less smoking, it is recommended to undergo screening at finite intervals so they get the best out of the economical way to test. It is extremely helpful for patients in low resource clinical settings. It has good sensitivity for central tumors compared to peripheral tumors.

ii) *Bronchial Techniques*: a) *Bronchial Brushing*: Cells are exfoliated using a brush from the periphery of the bronchial tree. A bronchoscope is used to guide the pathway. The cells obtained from brush are immediately fixed in alcohol. This technique has higher sensitivity than sputum cytology . Its sensitivity and accuracy is relatively high compared to sputum cytology. because direct visualization of lesion is possible.

b) *Bronchial Washing*: In this procedure, some amount of fluid is forced into the lungs through bronchoscope and the water or the washings is retrieved back. The washing contains requisite amount of fluid mixed with cells for cytological analysis.

c) *Brochoalveolar Lavage*: Cells are collected from airways and alveolar lining because at the alveolar level diseases are mostly existent. After an infusion of

buffered saline solution in the alveoli of lungs, the solution containing alveolar milieu is withdrawn back.

Table 4: A brief overview of different works in Lung cancer cytology identification where Accuracy (Acc), Jacard Index(JI), Specificity (Sp), Sensitivity(Se) and Dice Similarity Coefficient (DSC) are represented in their corresponding bucket given in abbreviated form.

Sl/#	Author's name	Name/Source(N/S) and Number of samples(Size) in the Dataset	Method for image segmentation	Features and classifier used	Quantitative results and Findings
1	Taber et al. (2015)[160]	N/S: Tokyo center of lung cancer in Japan. Size: 100 sputum color images.	Mean shift segmentation.	Features: N/C ratio, curvature, circularity, Eigen ratio, density. Classifier: ANN and SVM	Acc: 97% Se: 97% Sp: 96% Findings: Single sputum cell. Cell boundary not properly delineated.
2	Shajy et al. (2015)[144]	N/S: Regional Cancer center, Thiruvananthapuram, Kerala. Size: 32 training and 59 testing.	CLAHE and Otsu for image enhancement and segmentation respectively.	Features: DWT and GLCM separately Classifiers: SVM	Best result with DWT Acc: 89.8% Se: 89.3% Sp: 90.3% Findings: Overlapping of cell not considered.
3	Kecheril et al. (2015)[75]	N/S: Regional cancer centre, Thirubanthapuram, India. Size: 10 benign,24 malignant	Image localization using maximization of determination of Hessian in scale and k-means used for clustering.	Features: 690 scale space catastrophic point based on feature extracted in 32 scales Classifier: SVM	Acc: 87.53% Se: 76.95% Sp: 92.82% Findings: Only glandular cells are considered for segmentation, while missing some actual cells during segmentation.
4	Teramoto et al. (2017)[166]	N/S: Fujita Health University, Toyoake City,Japan. Size: 298 images from 76 cases.	Images are resized with 256 × 256 .	Features and classifiers: Developed 4 layer DCNN with 3 convolution layers, 3 pooling layers, and 1 forward connected layer with dropout.	Acc: 71% Findings: Unsatisfactory result due to non customized CNN architecture.
5	Dholey et al. (2018a)[30]	N/S: Medical College Kollata, and EKO centre Kollata, India. Size: 600 images from 120 samples	GMM based hidden MRF. Morphological filters used to remove unwanted regions.	Features: SIFT, Bag of word and visual dictionary after clustering. Classifiers: Random Forest	Acc: 98.88% Se: 97.31% Sp: 99.54 Findings: Description of samples are misleading.
6	Dholey et al. (2018b)[31]	N/S: Medical College Kolkata, and EKO centre, Kollkata, India. Size: 500 images from 100 samples.	Random walk with K-means. Watershed was used to remove unwanted regions.	Features: 25 features. (10 geometric, 14 texture features and 1 color based) Classifier: ANN and SVM.	Using ANN (Max) Acc: 97.46% Se:97.5% Sp:97.6% Findings: Description of samples are misleading.

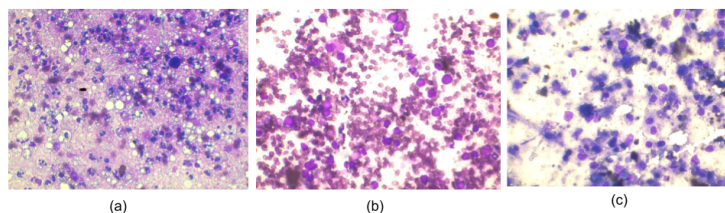


Figure 8: Samples of cytology images of Lung (a) Benign case (MGG stain, 40X magnification) (b) Malignant case (Small cell Lung Carcinoma, MGG stain, 40X magnification), (c) (b) Malignant case (Non-Small cell Lung Carcinoma, MGG stain, 40X magnification)

iii) *FNA*: Lung nodules are also aspirated using computer tomography (CT) guided FNA. It has three sub types [25]:

- a) *Transbronchial FNA*: For the lesions located in subbronchial regions, sensitivity of TBNA is 56% and specificity is 74%,
- b) *Transesophageal FNA*: It is done through endoscopy of esophagus. It is helpful in sampling of mediastinal lymph node,
- c) *Percutaneous FNA*: It is rapid diagnosis of pulmonary using sensitivity and specificity of 89% and 96% respectively.

4.3.2 *Differential characteristics associated with cytomorphology of lung malignant cells*

- Polygonal/round/fibre like cells.
- Abundant dense and smooth cytoplasm filled with keratin.
- Small hyperchromatic nucleus.
- Inconspicuous nucleolus.

4.3.3 *Significant works*

Ample amount of works in cervical and breast cytology can be seen in the literature with varied degrees of diversity. On the other hand, surprisingly, very few works are encountered in lung cancer cytology may be due to the lack of standard publicly available dataset. Samples of lung cytology images are shown in Fig. 8.

i) Segmentation based approach

Region based: Kancherla et al. [73] proposed seeded region growing segmentation method. On Biomada dataset they extracted 79 features related to shape, intensity, color, wavelet based features and nucleus segmentation based features to achieve an improved recognition accuracy of 87.8% using bagging on Random Forest.

Color based: Using color information as the key discriminating factor, Taher

et al.[158] and Donner et al.[37] put forward an efficient method for cell segmentation. Vineeth et al.[84] explored the impact of color representation on classification on lung sputum images and found that Bayesian Classifier was applied to classify the sputum cells into 3 different classes i.e. nucleus, cytoplasm and background with misclassification error rate zero using HSV values based feature vector.

Clustering based: Rachid et al. [131] proposed an unsupervised technique using HNN to cluster the pixels of sputum images into nuclei, cytoplasm and background classes. To escalate the accuracy of segmented regions Sammouda et al. [141], inserted an energy function having a cost term. However, the method suffers from early local minimum of HNN due to which the superimposed cells could not be delineated. In the study by [161], the sputum images were segmented into nucleus, cytoplasm and background using HNN based module. 8-connectivity was used to find connected component in nucleus. The proposed framework proved to be robust in systematic setting of the classification parameter. [159] proposed a Bayesian classification framework to investigate whether a pixel in the image belongs to sputum cell or not. HNN segmented the nucleus, cytoplasm and background region of 88 color sputum images. The segmentation accuracies using HNN and FCM were 88.62% and 64.91% respectively on HSV color space. Forseberg et al. [42] proposed an adaptive thresholding technique on whole-slide images of endobronchial ultrasound-guided TBNA. K-means clustering was used to segment the nucleus. A processing time of 7.8 seconds/Sample was reported in the experiment. Sarvaiya et al.[143] guided a sputum image segmentation technique by classifying colors using k-means clustering technique. Kecheril et al.[75] proposed a localization technique of cellular region by scale space based determinant of Hessian. Due to presence of non-cellular artifacts, Otsu's threshold method was adopted. K-means clustering was used to segment nuclei. 32 scales were generated and at each scale saddle maxima and saddle minima catastrophe points were calculated to generate 64 dimension feature vectors. For classification, SVM with RBF kernel were used with 10 fold cross validation.

Mean shift based: Werghe et al.[177] proposed a robust Bayesian classifier using RGB, HSV, YCbCr and L*a*b* colour spaces. The RGB and the HSV showed consistency in all resolutions. For the sputum cell segmentation, they used mean shift technique by a judicious choice of threshold parameter using both spatial and chromatic information. A reasonable accuracy of 85.51% was obtained which overule the traditional HNN showing the robustness of the used technique.

ii) Segmentation free approach Teramoto et al. [166] introduced CNN based approaches for classification of adenocarcinoma, squamous cell carcinoma, and small cell carcinoma without any segmentation. Data augmentation techniques were used to augment 298 samples to 5000 data. They obtained a recognition accuracy of 71.1%. Some significant works on lung cancer cytology are shown in Table 4.

Classification:

The articles on lung cytology are much confined compared to other domains of

cytology. Bayesian classifiers [177, 37], ANN [160, 31], SVM [75, 160, 144, 31], Random forest [30] etc. were popularly used in sputum cytology.

4.4 *Miscellaneous*

So far we have discussed different methodologies on three domains of cytology where majority of image processing techniques are applied. In this section, we will discuss the works on the rest of the fourteen types of cytology as available in literature. We have summarized this in a single section due to lack of sufficient works in these domains.

Some significant works are noticed in thyroid cytology [29, 190, 189]. Daskalakis et al. [29] reported a discriminating technique between malignant and benign cell of thyroid cytology image using pixel based techniques. From the segmented images 26 morphological and textual features were extracted and used for classification purpose. Four different classifiers were used for comparative analysis and maximum accuracy of 95.7% was reported using majority voting based combination techniques among KNN, PNN (parametric neural network) and Bayesian network. The experiment was carried on 53 benign and 62 malignant images, collected from the University hospital of Patras, Greece.

In [190, 189] Wu et al. used level set methods, watershed algorithm, conditional random field, expected maximization algorithm etc. for segmentation of multispectral cytology images works. Multispectral images were captured using photometric sensory CCD camera. Wu et al.[189] exploited the idea of spectral data using a multi layer CRF model with a bottom-up approach using local probabilistic model and an unsupervised top-down approach with a Probabilistic latent semantic analysis(PLSA) representation. PLSA was used to assign a latent topic to a pixel determined by Expectation-Maximization algorithm which was further upgraded by local mapping. This approach showed better accuracy in segmenting nucleus than seeded watershed in color images and also proved advantageous for low contrast and noisy environment.

Yang et al.[194] introduced an unsupervised segmentation technique for leukemia images. They estimated colour gradient and L2E into traditional GVF snakes in HSV colour space. Fifty eight lymphoproliferative cases of four types: "chronic lymphocytic leukemia (CLL), mantle cell lymphoma (MCL) and follicle-center cell lymphoma (FCC)" were considered. The data were taken from the "Hospital of the University of Pennsylvania", Philadelphia; "Robert Wood Johnson University Hospital", New Brunswick; and "City of Hope National Medical Center", Duarte. They reported better results than unsupervised approaches such as mean shift and colour GVF snake.

To identify the appropriate types of the *ovarian cancer* from cytology images, Wu et al. [187] proposed a CNN based approach using AlexNet. 85 labelled specimens in 4 categories namely: "serous carcinoma, mucinous carcinoma, endometrioid carcinoma, and clear cell carcinoma" were collected from "Xinjiang Medical University". 1848 ovarian cancer cytological images of 1360×1024 pixels dimensions were considered. They used rotation based augmentation technique

Table 5: A brief overview of different works in other cytology identification where Accuracy (Acc), Jacard Index(JI), Specificity (Sp), Sensitivity(Se)and Dice Similarity Coefficient (DSC) are represented in their corresponding bucket given in abbreviated form.

SL#	Author	Name/ Source and number of samples(Size) in dataset	Method in Image Segmentation	Features and Classifiers used	Quantitative results and Findings
1.	Wu et al.(2009)[191]	Thyroid FNAC smears	Morphological self dual reconstruction using Watershed algorithm.	Bhattacharyya distance	Acc:- 95.19% FP: 2.12% Findings:Only segmentation of the images. No standard dataset
2.	Gopinath et al.(2013)[49]	Thyroid FNAB collected from on-line image atlas of Papanicolaou Society of Cytopathology	Morphological operations Watershed transformation	Features: Two-level discrete wavelet decomposition GLCM, Gabor filters Classifiers: k-NN, ENN(Elman neural network),SVM	Acc: 93.33 % in ENN classifier by training statistical features Findings: CAD based system for multi-stain images.
3.	Sanyal et al.(2018) [142]	Thyroid FNAC smears collected from tertiary care centers of North India	Not applicable	ANN (Artificial Neural Network)	Combined result in 10x and 40x magnification: Se: 90.48% Sp: 83.33% negative predictive value :96.49% Acc: 85.06% Findings: No standard dataset
4.	Dimauro et al.(2018)[34]	superficial cells from the nasal mucosa collected from Rhinology Clinic of the Otolaryngology Department of the University of Bari	Otsu thresholding algorithm,morphological opening operation followed by labelling, marking objects	Classifiers: CNN(ConvNet) 1st approach: Data augmentation: geometric transformations (reflection,rotation, translation) 2nd approach: hyperparameter-optimization	Result: Acc: 94.0% Se: 96.4% Sp: 82.5% Findings: Low cost system for preparing report of rhino-cytogram.
5.	Hossain et al.(2019)[59]	Renal cytology collected from National Cancer Institute, USA	K-means clustering to classify background and nucleus region. SVM to differentiate between normal and abnormal nuclei regions. Selective search algorithm is used to detect irregular shaped structures in abnormal regions.	Features: patches of normal and abnormal cells. Classifier: RCNN used for normal and abnormal cell detection	Precision:99.01% Recall:98.7% F-measure:98.8% Findings:proliferation rate estimation for successful prognosis of the disease.
6.	Dimauro et al.(2019)[33]	14 Nasal cytology images collected from Rhinology Clinic of the Otolaryngology Department of the University of Bari	K-means clustering to classify background and nucleus region. SVM to differentiate between normal and abnormal nuclei regions. Selective search algorithm is used to detect irregular shaped structures in abnormal regions.	Classifier: CNN	Result of test set on 7 class problem Se: 98.6% Sp: 99.7% Acc: 99.4% Findings: Manual acquisition of fields. No standard dataset.

to increase the dataset into 20,328 samples. The images were divided into four sub images and resized them to 227×227 . After data augmentation they got accuracy of 78.20% using AlexNet on 10 fold cross validation.

5 COMMERCIALY AVAILABLE SYSTEMS

The core idea to insert robust features with proper segmentation techniques is to build smart user-end systems capable of handling large amount of data. Thus, it could reduce the workload of the cytotechnologists. Evolution of automation system for cytological images has started since 1950. With the improvement in slide preparation techniques, some systems became obsolete and some modified accordingly. New systems evolved with better techniques and high computation powers. There are a series of systems available for cervical cytology, but for breast cancer and lung cancer very few systems are found at one's disposal. Unfortunately most of the systems are not commercially available in the market. Some of the popular commercially available systems are recorded in the Table 6.

Table 6: Different commercially successful Cytology based systems

Manufacturer and year of manufacturing	Cancer pre-screening systems	Description	Assessment
Airborne Instruments Laboratory, Inc., N. Y., 1950	Cytoanalyzer	An electronic optical machine to detect abnormal pap smear cells. The machine consists of a scanning microscope, computer and analyzer, and recorder. The scanner examines the significant area of the smear and converts the optical information into an electric beam which is passed to the computer and analyzer.	Two sets of experiments were conducted between 1958-1960 and results reveal high false negative cases which hindered to make it commercially available [167, 145].
Watanabe and Toshiba, 1972	CYBEST	The pap smear screening system that uses object extraction techniques like thresholding and differential approaches. It uses morphological features nuclear size, N/C ratio, optical density, nuclear shape, chromatin pattern for image analysis. The model was upgraded to model 2 (1974), model 3 (1978) and model 4 (1981) accordingly with improved designs and reduced turnaround time.	Field tests of CYBEST model 4 shows occurrences of greater false positive cases. CYBEST model 4 takes nearly 3 minutes per specimen to evaluate [162].
DJ Zahniser ,1979	BioPEPR system	It was designed to prescreen cervical smear based on cellular morphology nuclear area, nuclear optical density, nuclear texture, and N/C ratio. Additional programs were designed to recognize artifacts, overlapping nuclei and leukocytes.	A high false alarm rate of 24%, restricted commercial feasibility and also efficiency was highly dependent on quality of smears. Analysis rate was 4 minutes/smear [55].
BD Diagnostics (Sparks, MD)	Focal Point Slide Profiler (FDA approval in 2006)	It is an FDA approved system that screens the entire slide. A Focal Point Score was derived from the slide using a model based on different features such as nuclear size, contour, ratio with cytoplasm, integrated optical density. A score less than a threshold is separated into "Further Review" category	For glandular abnormalities, FocalPoint screened slides need to be reviewed exhaustively regardless of the quintile ranking. Also it was not cost effective and required heavy technical maintenance [125].
Tripath (1998) formed with three companies Neopath, Neuromedical and Autocyte	Autoprep 300 (FDA approved in 1998)	A first FDA approved rescreening system that infused neural network using morphological features into low level programming. It used two resolution levels: low resolution to map the specimen and high resolution for selecting ROI. Only suspicious samples detected was labeled as 'Required Visual Inspection'. The image processing system was developed using specific system board ASIC.	The system is confirmed for 25% cases without further screening as normal cases. Rest of the cases are categorized into five different stages of abnormality [173].
Hologic, Inc., taken over from Cytex Corp, Marlborough, MA	ThinPrep® Integrated Imager (T- 3000) (FDA approval in 2018.	Designed for pap tests, it consists of a single desktop system using an imaging station and microscope and directs technicians to examine only potentially abnormal areas.	Increased throughput by detecting only suspicious cells without complete manual slide review. It reviews a slide in ~90 seconds [58].
Neuromedical Sciences Inc (NSI) Late 1990s	PAPNET Systems	A rescreening system that infused neural network into low level programming. It used two resolution levels: low resolution to map the specimen and high resolution for selecting ROI. Only suspicious samples detected was labeled as 'Required Visual Inspection'.	Not cost effective and no hint of malignancy either. In the end of 1999, NSI was exhausted of capitals and declared an economic failure to run the project [80].
C-DAC along with the RCC, Trivandrum	CerviSCAN	This pap smear screening system has a Piezo server controller connected to a microscope. It captures the information of a nucleus at various foci and stacks the information for every nuclei.	Creating image stack required expert intervention and huge memory. Also, collecting information of nucleus at various focus hindered by background debris [170].
W.N Street,1990, University of Wisconsin Madison.	"Xcyst project"	A breast cancer diagnosis and prognosis system.	More false negative cases [154].
Roger A. Kemp 2007	LungSign test	LungSign is a fully automated system for analysis of sputum specimens to scan slides automatically. Using cellular morphology it produces a score for individual specimen.	LungSign is an effective tool for detecting stage 1 cancer and needs to be upgraded for high stage cancers [77].

6 AUTHORS VIEW

During the journey towards automation in cytology, we clearly make out the goals and achieved solutions. The primary goal is to help cytotechnologists to reduce turnaround time with lesser “false” cases. Though none of the false cases are desired either, false negative cases should be totally delimited, from diagnostic point of view. Because one false negative case would leave the patient untreated leading to a fatal situation. False positive cases, on the other hand, puts the patient in a traumatic condition. Thus, machine driven output should be at least comparable to human evaluation. The second goal is obviously the cost effectiveness, so that it can be run in low resource clinical settings.

Some of the major segmentation techniques found extensively in literature are jotted down in Table 7. It is observed that a lot of experiments have been done on cervical and breast cancer detection whereas the number of algorithms explored for other types of cancers are very few. This survey points out the progress of automation in terms of research to reach to a viable commercial output. During the period of 1988 to 1998, though meagre amount of cytology based research works are registered, most of the researches tend to concentrate towards contour and deformable contour models as depicted in Fig. 9. During the period of 1998 to 2008 texture based features using wavelet analysis were in vogue. During the last decade, deformable contour models and clustering based segmentation approach showed unprecedented pace jointly bagging almost 45% of the research works using rest of the segmentation techniques. As neural network based deep learning techniques has become the cutting edge technology from past few years due to its automatic feature learning mechanism, it is slowly replacing previously used classification techniques using KNN, Random Forest, SVM etc. Despite its successful implementation in several areas of research its performance is largely dictated by an exhaustive dataset which has paucity in cytology domain .

Though there are diverse and plenty of works in cervical and breast cytology domain, a little less is realized in lung cytology. At the same time the research works on histopathology images of lung are much more pronounced and diverse compared to cytology. It is observed, that methodologies in lung cytology tend to concentrate towards particular techniques. So, techniques also lack diversity at the end. Also, majority of the techniques produce only segmented images. Thus, end user’s interference is mandatory. Again, works exist only in sputum cytology whereas other modalities of cytology in lung cancer detection are almost unattended creating a large void and opportunity to work on those modalities, thereby exploring possibilities to generate high degree of recognition accuracy.

Developing certified systems for automotive application requires a deep insight of the functionality of the design including power, cost and time to market to help ensure market success. Although, some automated devices have become de facto medical standard in few parts of the world, third world countries like, India, are still to exploit the advantage of the screening devices on a full scale. So, efforts are now streamlined towards producing screening unit that can be op-

erated in a semi-automated fashion. Researches are presently heading towards producing intelligent and remote web-based diagnostic system which can handle a large group of patients with reduced false cases. It is observed that false cases are almost part and parcel of automated systems. Despite several disadvantages, many software and hardware automated systems are available in laboratories that act as human companion, assisting in various decision making processes by generating a reference from a machine generated output. Existing systems though require end users interaction, nevertheless they reduced the workload to a greater extent. Thus, cytotechnologists apart from reviewing slides can also join in research activities.

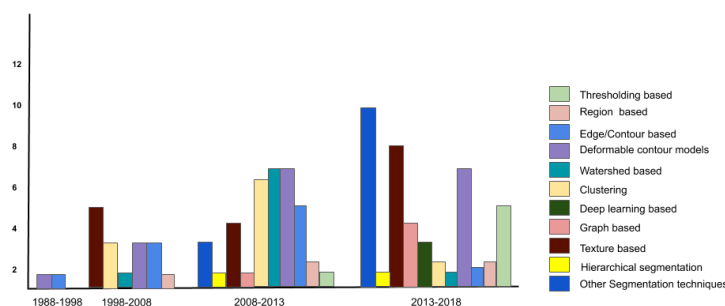


Figure 9: Major segmentation techniques and their usages in last three decades on cytology images

Table 7: Major segmentation algorithms used in cytology images

Sl#	Segmentation techniques	Methodologies
1	Thresholding based	a. Otsu thresholding [164], b. Modified Otsu with class prior probability [83] c. Adaptive thresholding method [203];[2];[85], d. Iterative adaptive classified algorithm [207]
2	Region based	a. Seed based region growing [73], b. MSBRG [101]; [90], c. MSER [95] d. Grow-Cut [61], e. Anisotropic diffusion and anisotropic kernel mean shift [164]
3	Edge/Contour based	a. CNC detector[168]; [123], b. EENCC detector[196], c. Sobel edge detector[148] d. Non-maximum suppression [90], e. Hough transform[153]; [60], f. Compact Hough transform [106] g. Two-group edge enhance method [90], h. Laplacian, Prewitt, Roberts, Robinson[101], i. Superpixel Partitioning and Cell-Wise Contour Refinement [85]
4	Deformable contour models	a. Active Contour Model [194];[164], b. Hough transform with deformable models [86], c. Adaptive active contour modelling [200], d. Snake model [184];[6];[116], e. GVF snakes[97], f. Radiating GVF Snake [88];[140], g. Dynamic sparse contour and GVF Snake [51], h. Viterbi search-based dual ACM [135], i. Level set method[109];[90];[190], j. Joint level set [95], k. Multiple level set[94], l. Level set method active contour model[39] m. Multi-step level set method [67]
5	Watershed based	a. Watershed based [61], [128];[108];[120]; [147], b. Multi-pass fast watershed[31], c. Multi scale Watershed[72], d. Colour based watershed [87], e. Hierarchical watershed [121]
6	Texture based	a. Coarseness [197], b. Texture Filter Bank [11], c. Scale space features[75] d. Wavelet transforms [178]; [68]; [5], e. Gray Level Co-Occurrence Matrix [174]; [155] f. Gabor[116];[133];[108];[41], g. Rotation invariant LBP [119] h. Conventional LBP[41], rotation invariant patterns, local patterns with anisotropic structure, completed local binary pattern (CLBP) and local ternary pattern (LTP)[52]
7	Graph based	a. Graph cut [202], b. Global and local graph cuts[204];[187] c. Graph search [205], d. Graph-search based MRF- [207]
8	Clustering	a. Spatial k-means [88], b. k-means clustering algorithm[101];[42] c. Fuzzy C means clustering[79];[146];[138];[65] , d. Spatial patch based Fuzzy C-means clustering [22], e. GMM based [152];[82];[132], f. GMM with HMRF[30], g. Superpixel based MRF [207], h. SLIC[130], i. Superpixel Partitioning and Cell-Wise Contour Refinement [85], j. Entropy based superpixel method [105], k. SuperPixel with Voronoi[171]
9	Hierarchical segmentation	a. Hierarchical shape approximation, and shape regularization [164] b. Spectral and shape information based non-parametric hierarchical segmentation algorithm[132]
10	Deep learning based	a. Multiscale CNNs [149], b. Multiscale CNN and graph based partitioning [150] c. Deep learning and dynamic shape modeling[165]
11	Other Segmentation techniques	a. Colour based [203];[57];[12]; [65]; [18], b. Phansalkar's local search[171] c. Intersecting Cortical Model (ICM) [163];[5], d. Spatially adaptive active physical model [129] e. Minimax optimization of an energy functional[2], f. Mean Shift[187] g. QPSO with Fuzzy KNN[205], h. Star shape prior and Voronoi energy term[118]

7 CONCLUSION

This article reviews and captures the diversity of the state-of-the-art methodologies in the analysis of cytology images. It starts with a brief introduction of cytology. Steps required to prepare a cytology specimen are subsequently discussed. In the following section we tabularize 17 different types of cytology along with the modalities of specimen collection from patients and also their challenges in detecting the disease. We have pointed out that most of the existing literature revolve around cervical and breast cytology, and other domains in cytology do not receive much of researcher's attention. We have also realized that some segmentation frameworks surpass all the previous results following the recent trends of Deep learning module, while other traditional/conventional methodologies pay attention to segment the cells using handcrafted features of nucleus. To be precise, we can now encapsulate some of the outcomes of this article as possible future directions to bring the cytology commercial systems into the mainstream. Below are summarized some of the areas in cytology where there are ample scope for upgradations:

- Lack of freely available standard datasets for cytological images, except for pap smear cytology. Again, the size of the available datasets are not sufficient enough to train a deep learning module effectively.
- Appropriate segmentation algorithm is yet to be designed for segmentation of clusters of overlapped nuclei. In addition, majority of the segmentation algorithms are developed focusing on supervised data, whereas robust unsupervised algorithms need to be developed for automatic labelling of data.
- Absence of standardized staining technique hinders the segmentation techniques to be appropriately implemented.
- Processing high resolution images with conventional segmentation techniques is time taking.
- Non availability of viable commercial systems apart from pap smear images.
- There exist no single system for handling cytological images in different domains.

Possible future directions to successfully run the existing systems can be enumerated below:

- The limitation of available standardized dataset can be overcome by synthetically generating realistic dataset using contemporary deep learning techniques, such as Adversial Neural Network, Variational Autoencoder etc.
- Appropriate resizing techniques [48] need to be grabbed for feeding deep learning modules

- Parallelization of algorithms can aid to make computational time faster.
- Implementation of techniques for hand-held devices using different embedded modules, such as Raspberry Pi, Arduino etc.

The automatic understanding the nature of cytology images is a challenge to the researchers because of their diverse nature and presence of unusual artifacts. Some systems that are available for cervical, breast and lung cancer are not robust enough to deal with all kinds of the data existing globally, so could not be marketed in a large scale. Also, production of high precision screening machines are not very cost-effective. All these factors coagulated to hinder the current screening systems reaching the third world countries like India. So, efforts are now streamlined towards finding a feasible solution or a screening unit that can at least be run in a semiautomatic fashion. The success in this regard, till date, is limited. Still there is a lot of scope to work in this domain due improvements in data collection methodology and staining techniques. We, finally, hope that this survey will help the researchers to comprehend the latest state-of-the-art methods and progress of cytology based research for systematic and selective design of algorithms and test ideas to develop a conceptual framework suitable for analysis in relevant problem domain.

Acknowledgement

This work is partially supported by SERB (DST), Govt. of India sponsored project (order no. EEQ/2018/000963 dated 22/03/2019). Authors are also thankful to the members of "Theism Medical Diagnostics Centre", Kolkata, India and "Saroj Gupta Cancer Centre & Research Institute", Thakurpukur, Kolkata, India.

Supplementary Information

Specimen Collection

In any cytological test, collection of specimen is the first step where pathologists collect cells from the predetermined mass for pathological analysis. Based on collection techniques cytology can be broadly categorized under three heads: 1) *Aspiration cytology* 2) *Exfoliative cytology* 3) *Abrasive cytology* as shown in Fig 10.

1. **Aspiration cytology** In this study or procedure, cells are aspirated *i.e* taken out by using a fine needle normally of 23-25 gauge from body fluid, cyst or palpable mass of clinical suspicion. Prior to injection, the suspected region is cleaned by swabbing with a cotton soaked in antiseptic solution. A well known example of aspiration cytology is FNA. It is extensively used in the detection and diagnosis of breast lumps, liver lesions, renal lesions, ovarian masses, soft tissue masses, pulmonary lesions, thyroid nodules, subcutaneous soft tissue mass, salivary gland, lymph nodes etc. [93]. This

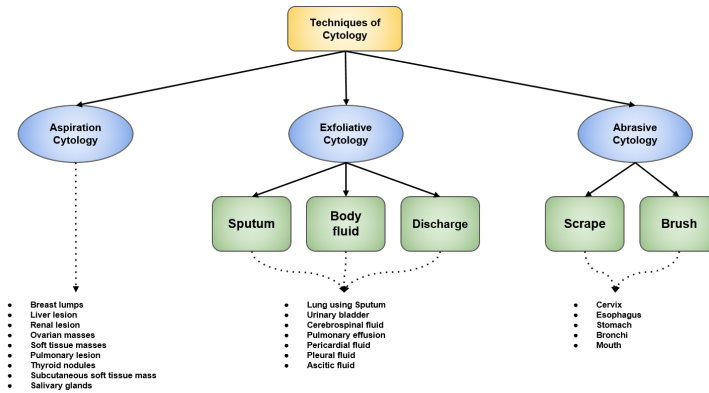


Figure 10: Different types of specimen collection techniques and their associated domains in cytology

process is relatively faster, safer, cheaper, non-invasive and less painful method when compared to surgical biopsy [36]. Serious complications are very rare and include redness, soreness and minor hemorrhage. First FNAC was done at Maimonides Medical Center, United States, in 1981 successfully which paved the way to an almost painless and trauma free diagnosis process.

2. **Exfoliative Cytology** It is the study of micro examination of desquamated cells from the body surfaces or cells that are harvested by rubbing or brushing a lesional tissue surface. It consists of three sub types:-

(i) Body fluid cytology: This includes:

- Urine
- Cerebrospinal fluid (CSF) is a fluid that surrounds the brain and spinal cord.
- Pleural fluid (pulmonary effusion) is an accretion of fluid in the lining of tissues between lungs and the chest cavity.
- Pericardial fluid is secreted by the serous layer of the pericardium into the pericardial cavity surrounding the heart.
- Ascetic fluid also called ascites or peritoneal fluid, refers to abnormal accumulation fluid in peritoneal or abdominal cavity.

(ii) Discharge cytology: In this category, cytological examination of breast secretions are carried out to diagnose the disease. (iii) Sputum cytology: Sputum is a popular exfoliative cytology which is usually used for lung disease detection. Sputum (phlegm) is a mixture of mucus and saliva consisting of exfoliated epithelial cells that line the respiratory tract. It is

spontaneous (often aerosol induced) and is coughed up from the lower respiratory tract i.e trachea and bronchi. Cytological examination of sputum is done under microscope to detect presence of malignant cells.

3. Abrasive Cytology

In this procedure, the sample is collected directly from the surface of the region of interest using superficial scraping or brushing of the lesion (artificial mechanical desquamation).

- (a) Scrape cytology: This technique deals with exfoliation of cells with the help of scrape or brush from the organ or the region being tested. Pap-smear test is a well known screening test of this kind. Buccal mucosal smear, skin scraping, esophagus, stomach, etc. also fall under this category.
- (b) Brush cytology: It is used to collect cell samples from the gastrointestinal tract, bronchial tree, cervix etc.

Slide Preparation

It is one of the important steps for the diagnosis of carcinoma from cytology images that is equally necessary for both manual and automatic diagnosis system. After preparing the slide suitably, the fixation is required. Two kinds of slide preparation techniques are normally performed in laboratory on the collected specimen.

1. *Conventional Preparations*

After collection, specimen is expelled into appropriately labelled glass slides with patient's unique identification. The expelled material is spread over several slides in small amounts, rather than deposited in one large pool on a single slide to enhance the probability of error free interpretation. This simplifies the process to obtain a thin-layer preparation. Spreading of the material over the slide is usually performed by another sliding glass slide, in order to avoid crushed artefacts and obtain a uniform smear. Large amounts of blood is avoided to prevent clotting and fibrin trapping in the cells, which creates large cracks on the slide hindering interpretation at cellular level.

2. *Liquid-Based Preparations*

It was introduced initially for cervical smears, and nowadays it is also used for other types of specimen, including FNA, because this technology has added advantages compared to conventional smears. Three preparatory steps are undertaken viz. cell dispersion, collection and transfer to prepare an appropriate slide. After collecting the specimen, the aspirate is rinsed directly into a container filled with 20 ml. of CytoLyt or CytoRich transport solution which is an alcohol-based solution (see Fig. 11). If a fresh, non-alcohol-fixed specimen is indicated clinically, the specimen is put into

a balanced electrolyte solution. Two commonly used liquid-based preparation techniques include ThinPrep (TP)[26] (Cytoc Corp, Marlborough, MA) and BD SurePath (SP)[117] (TriPath Imaging Inc., Burlington, NC). Liquid based preparations offers several advantages over conventional preparations:

- Abundant cellularity in the specimen can be observed.
- Immediate liquid fixation avoids air-drying artifacts.
- Free from background contaminations like cell clumps, blood and mucus are very rare due to advanced preparatory techniques, give a good background clarity.
- Nuclear and cytoplasmic architecture are well maintained with reduced overlapping.
- Normalized specimen.
- It has potential capability for processing residual material as a cell-block.

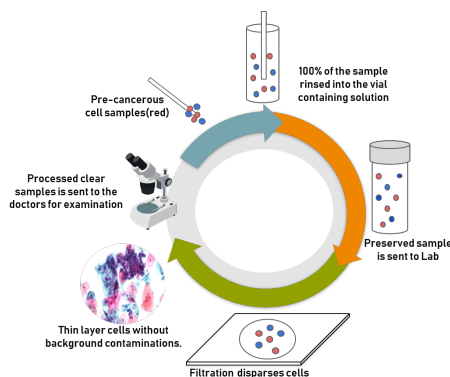


Figure 11: Steps to prepare thin prep cytology specimen

Fixation Techniques and Staining Protocol

Immediate fixation of the collected specimen is crucial, otherwise it produces drying artifact leading to false positives or false negatives cases in medical diagnosis. Two types of fixation techniques are practiced in laboratories: Air drying and Alcohol drying. Staining is also an essential step which is usually done after fixation of cytology specimen. Majority of the stains generally fascinates lights and illuminating samples under it. Without staining, it is not possible to identify the selective regions of different tissue samples. The quantity of illumination on a sample or portion of sample depends on the amount and type of stain. However, the same type of stain may vary on multiple factors such as manufacturer of stain, procedure of preservation and also the condition of specimen before use, etc. [96]. Even in case of specimen expertise of cytology, it may

Table 8: Some special stains and applicability

Special Stains	Requirement
Modified Ziehl Neelson [4]	Acid fast bacilli smear and culture
Gram staining [50]	Bacteria
Mucicarmine [24]	Mucins
PAS(Periodic Acid-Schif [175])	Glycogen, Fungal wall, Lipofuscin
Oil red O [134]	Lipids
Perl's Prussian blue [53]	Iron
Modified Fouchet's Test [16]	Bilirubin

vary from one cytotechnologist to another. The intensity can vary depending upon the amount of time it remains under the air drying process.

1. *Air Drying* After preparation of the slides, they are immediately fixed by air drying preferably within 5 minutes. Romanowsky stains [182] are usually applied to air-dried smears. It's staining protocol includes May Grunwald Giemsa (MGG) [17], Leishman Giemsa(LG) [35], Diff quick stain etc. MGG is the most commonly used staining technique to extract cellular morphology and cytoplasm details from air-dried smears. Tubercle bacilli, Actinomyces, some fungal elements appear red and background appear pale blue in color on application of this particular stain.

2. *Alcohol Fixation*

Alcohol or wet fixation is achieved either by using a spray fixative or dipping the slides in 95% ethyl alcohol. Papanicolaou stain [9] is normally preferred for the staining of alcohol fixed slides. Squamous differentiation can be best appreciated by Papanicolau stain. The staining protocol includes Papanicolaou-EA-50, to stain critical portions of nucleus and cytoplasm. Harris hematoxylin [89] is a combination of OG6 (Orange G) and EA50 (Eosin Azure). OG6 is a pap reagent for counter staining exfoliative cytology samples like vaginal, cervical, prostatic smears etc. After application of the stain the nucleus appears blue/black. The cytoplasm for keratinising cells appears pink or orange and blue or green in colour for non-keratinising squamous cells.

Some special stains are mentioned in Table8.

References

- [1] Azian Azamimi Abdullah, Aafion Fonetta Dickson Giong, and Nik Adilah Hanin Zahri. Cervical cancer detection method using an improved cellular neural network (cnn) algorithm. *Indonesian Journal of Electrical Engineering and Computer Science*, 14(1):210–218, 2019.
- [2] P Agarwal, A Sao, and A Bhavsar. Mean-shift based segmentation of cell nuclei in cervical PAP-smear images. In *2015 Fifth National Conference on Computer Vision, Pattern Recognition, Image Processing and Graphics (NCVPRIPG)*, pages 1–4, 2015.
- [3] I Al and J S Ploem. Detection of suspicious cells and rejection of artefacts in cervical cytology using the Leyden Television Analysis System. *The journal of histochemistry and cytochemistry : official journal of the Histochemistry Society*, 27(1):629–634, 1 1979.
- [4] JANET L Allen. A modified ziehl-neelsen stain for mycobacteria. *Medical laboratory sciences*, 49(2):99–102, 1992.
- [5] G Anna Lakshmi, S Ravi, G. Anna Lakshmi, and S Ravi. Automated segmentation algorithm for cervical cell images by employing cuckoo search based ICM. *Journal of Ambient Intelligence and Humanized Computing*, pages 1–11, 11 2017.
- [6] Pascal Bamford and Brian Lovell. Unsupervised cell nucleus segmentation with active contours. *Signal Processing*, 71(2):203–213, 1998.
- [7] Eleanor P. [Editor] Banks. Cervical cancer research trends (nova biomedical). 2007.
- [8] Christoph Bergmeir, Miguel García Silvente, and José Manuel Benítez. Segmentation of cervical cell nuclei in high-resolution microscopic images: A new algorithm and a web-based software framework. *Computer Methods and Programs in Biomedicine*, 107(3):497–512, 2012.
- [9] Todd K Berkan, Jay E Reeder, Peter A Lopez Jr, Kevin M Gorman, and Leon L Wheelless Jr. A protocol for papanicolaou staining of cytologic specimens following flow analysis. *Cytometry: The Journal of the International Society for Analytical Cytology*, 7(1):101–103, 1986.
- [10] Kangkana Bora, Manish Chowdhury, Lipi B. Mahanta, Malay K. Kundu, and Anup K. Das. Pap smear image classification using convolutional neural network. *Proceedings of the Tenth Indian Conference on Computer Vision, Graphics and Image Processing - ICVGIP '16*, pages 1–8, 2016.
- [11] Kangkana Bora, Manish Chowdhury, Lipi B. Mahanta, Malay Kumar Kundu, Anup Kumar Das, and Anup Kumar Das. Automated Classification of Pap Smear Image to Detect Cervical Dysplasia. *Computer Methods and Programs in Biomedicine*, 138(1):31–47, 1 2017.

- [12] Omelkhir Boughzala. Automatic segmentation of cervical cells in Pap smear images. In *24th Conference on Computer Graphics, Visualization and Computer Vision 2016*, pages 343–349, 2016.
- [13] Cathy J Bradley, Charles W Given, and Caralee Roberts. Disparities in cancer diagnosis and survival. *Cancer*, 91(1):178–188, 1 2001.
- [14] Eliezer Farrant Braz and Roberto De Alencar Lotufo. Nuclei Detection Using Deep Learning. In *BRAZILIAN SYMPOSIUM ON TELECOMMUNICATIONS AND PROCESSING OF SIGNALS*, pages 1059–1063, 2017.
- [15] Alex brolo, 2006.
- [16] Daphne Bryant and FV Flynn. An assessment of new tests for detecting bilirubin in urine. *Journal of clinical pathology*, 8(2):163, 1955.
- [17] Paul Lopes Cardozo. *Clinical cytology: Using the May-Grünwald-Giemsa stained smear. 2. Atlas*. Stafleu, 1954.
- [18] Fabiana Pirani Carneiro, Maria Imaculada Muniz-Junqueira, Fabio Pittella-Silva, Marcos De Vasconcelos Carneiro, Gustavo Henrique Soares Takano, Leonora Maciel De Sousa Vianna, Luciano Barbosa De Andrade, Tercia Maria Mendes Lousa De Castro, Isabela Peres, Tatiana Karla Dos Santos Borges, Vânia Moraes Ferreira, and Andrea Barretto Motoyama. A panel of markers for identification of malignant and non-malignant cells in culture from effusions. *Oncology Reports*, 38(6):3538–3544, 2017.
- [19] Anne E Carpenter, Thouis R Jones, Michael R Lamprecht, Colin Clarke, In Han Kang, Ola Friman, David A Guertin, Joo Han Chang, Robert A Lindquist, Jason Moffat, Polina Golland, and David M Sabatini. CellProfiler: image analysis software for identifying and quantifying cell phenotypes. *Genome Biology*, 7(10):1–11, 10 2006.
- [20] Turgay Celik and Tardi Tjahjadi. Texture Classification and Retrieval Based on Complex Wavelet Subbands. In Erol Gelenbe, Ricardo Lent, Georgia Sakellari, Ahmet Sacan, Hakki Toroslu, and Adnan Yazici, editors, *Computer and Information Sciences*, pages 259–264, Dordrecht, 2010. Springer Netherlands.
- [21] Thanatip Chankong, Nipon Theera-Umpon, and Sansanee Auephanwiriyakul. Cervical Cell Classification using Fourier Transform BT - 13th International Conference on Biomedical Engineering. pages 476–480, Berlin, Heidelberg, 2009. Springer Berlin Heidelberg.
- [22] Thanatip Chankong, Nipon Theera-Umpon, and Sansanee Auephanwiriyakul. Automatic cervical cell classification using patch-based fuzzy clustering and minimum average correlation energy filter. In *IFMBE Proceedings*, volume 43, pages 164–167, 2014.

- [23] Thanatip Chankong, Nipon Theera-Umpon, and Sansanee Auephan-wiriyakul. Automatic cervical cell segmentation and classification in PAP smears. *Computer methods and programs in biomedicine*, 113(2):539–556, 2014.
- [24] James H Cherry and Ralph K Ghormley. A histopathological study of the synovial membrane with mucicarmine staining. *JBJS*, 20(1):48–56, 1938.
- [25] Edmund S Cibas and Barbara S Ducatman. *Cytology E-Book: diagnostic principles and clinical correlates*. Elsevier Health Sciences, 2013.
- [26] David J Dabbs, Catherine S Abendroth, Ronald T Grenko, Xiaohong Wang, and Gail E Radcliffe. Immunocytochemistry on the thinprep® processor. *Diagnostic cytopathology*, 17(5):388–392, 1997.
- [27] Goodarz Danaei, Stephen Vander Hoorn, Alan D Lopez, Christopher J L Murray, and Majid Ezzati. Causes of cancer in the world: comparative risk assessment of nine behavioural and environmental risk factors. *The Lancet*, 366(9499):1784–1793, 2005.
- [28] P. Das, T. Chatterjee, S. Chakraborty, D. Mondal, and N. Das. A texture based approach for automatic identification of benign and malignant tumor from FNAC images. In *2015 IEEE 2nd International Conference on Recent Trends in Information Systems (ReTIS)*, pages 249–254, 7 2015.
- [29] Antonis Daskalakis, Spiros Kostopoulos, Panagiota Spyridonos, Dimitris Glotsos, Panagiota Ravazoula, Maria Kardari, Ioannis Kalatzis, Dionisis Cavouras, and George Nikiforidis. Design of a multi-classifier system for discriminating benign from malignant thyroid nodules using routinely h&e-stained cytological images. *Computers in Biology and Medicine*, 38(2):196 – 203, 2008.
- [30] Moumita Dholey, Maitreya Maity, Atasi Sarkar, Amita Giri, Anup Sadhu, Koel Chaudhury, Soumen Das, and Jyotirmoy Chatterjee. Combining GMM-Based Hidden Markov Random Field and Bag-of-Words Trained Classifier for Lung Cancer Detection Using Pap-Stained Microscopic Images. In Siddhartha Bhattacharyya, Nabendu Chaki, Debanjan Konar, Udit Kr. Chakraborty, and Chingtham Tejbanta Singh, editors, *Advanced Computational and Communication Paradigms*, pages 695–705, Singapore, 2018. Springer Singapore.
- [31] Moumita Dholey, Atasi Sarkar, Maitreya Maity, Amita Giri, Anup Sadhu, Koel Chaudhury, Soumen Das, and Jyotirmoy Chatterjee. A Computer Vision Approach for Lung Cancer Classification Using FNAC-Based Cytological Images. In Bidyut B Chaudhuri, Mohan S Kankanhalli, and Balasubramanian Raman, editors, *Proceedings of 2nd International Conference on Computer Vision & Image Processing*, pages 181–195, Singapore, 2018. Springer Singapore.

- [32] E. G. Diacumakos, Emerson Day, and M. J. Kopac. Exfoliated Cell Studies and the Cytoanalyzer. *Annals of the New York Academy of Sciences*, 97(2):498–513, 9 1962.
- [33] Giovanni Dimauro, Giorgio Ciprandi, Francesca Deperte, Francesco Girardi, Enrico Ladisa, Sergio Latrofa, and Matteo Gelardi. Nasal cytology with deep learning techniques. *International journal of medical informatics*, 122:13–19, 2019.
- [34] Giovanni Dimauro, Francesco Girardi, Matteo Gelardi, Vitoantonio Bevilacqua, and Danilo Caivano. Rhino-cyt: A system for supporting the rhinologist in the analysis of nasal cytology. In De-Shuang Huang, Kang-Hyun Jo, and Xiao-Long Zhang, editors, *Intelligent Computing Theories and Application*, pages 619–630, Cham, 2018. Springer International Publishing.
- [35] Shilpa Manigatta Doddagowda, Hemalatha Anantharamaiah Shashidhar, and Chinaiah Subramanyam Babu Rajendra Prasad. Leishman-giemsa cocktail-is it an effective stain for air dried cytology smears. *Journal of Clinical and Diagnostic Research: JCDR*, 11(3):EC16, 2017.
- [36] Henryk A. Domanski. Fine-needle aspiration cytology of soft tissue lesions: Diagnostic challenges. *Diagnostic Cytopathology*, 35(12):768–773, 2007.
- [37] C Donner, N Werghi, F Taher, and H Al-Ahmad. Cell extraction from sputum images for early lung cancer detection. In *2012 16th IEEE Mediterranean Electrotechnical Conference*, pages 485–488, 2012.
- [38] R Erhardt, E R Reinhardt, W Schlipf, and W H Bloss. FAZYTAN: a system for fast automated cell segmentation, cell image analysis and feature extraction based on TV-image pickup and parallel processing. *Analytical and quantitative cytology*, 2(1):25–40, 1980.
- [39] J Fan, R Wang, S Li, and C Zhang. Automated cervical cell image segmentation using level set based active contour model. In *2012 12th International Conference on Control Automation Robotics Vision (ICARCV)*, pages 877–882, 12 2012.
- [40] Pawel Filipczuk, Thomas Fevens, Adam Krzyzak, Roman Monczak, Adam Krzy, and Roman Monczak. Computer-aided breast cancer diagnosis based on the analysis of cytological images of fine needle biopsies. *IEEE Transactions on Medical Imaging*, 32(12):2169–2178, 2013.
- [41] Paweł Filipczuk, Bartosz Krawczyk, and Michał Woźniak. Classifier ensemble for an effective cytological image analysis. *Pattern Recognition Letters*, 34(14):1748–1757, 2013.
- [42] D. Forsberg and N. Monsef. Evaluating cell nuclei segmentation for use on whole-slide images in lung cytology. In *2014 22nd International Conference on Pattern Recognition*, pages 3380–3385, Aug 2014.

- [43] Hrushikesh Garud, S. P. K. Karri, Debdoot Sheet, Jyotirmoy Chatterjee, Manjunatha Mahadevappa, Ajoy K. Ray, Arindam Ghosh, and Ashok K. Maity. High-Magnification Multi-views Based Classification of Breast Fine Needle Aspiration Cytology Cell Samples Using Fusion of Decisions from Deep Convolutional Networks. In *2017 IEEE Conference on Computer Vision and Pattern Recognition Workshops (CVPRW)*, pages 828–833, 2017.
- [44] Srishti Gautam, Harinarayan K. K., Nirmal Jith, Anil K. Sao, Arnav Bhavsar, and Adarsh Natarajan. Considerations for a PAP Smear Image Analysis System with CNN Features, 2018.
- [45] Asli Genctav, Selim Aksoy, and Sevgen Onder. Unsupervised segmentation and classification of cervical cell images. *PATTERN RECOGNITION*, 2012.
- [46] Y M George, H H Zayed, M I Roushdy, and B M Elbagoury. Remote Computer-Aided Breast Cancer Detection and Diagnosis System Based on Cytological Images. *IEEE Systems Journal*, 8(3):949–964, 2014.
- [47] Arnab Ghosh, Dilasma Ghartimagar, Manish Kiran Shrestha, P. K. Tiwari, Raghavan Narasimhan, and O. P. Talwar. Value of image-guided fine-needle aspiration cytology - A study of 500 cases. *Diagnostic Cytopathology*, 41(12):1052–1062, 2013.
- [48] Swarnendu Ghosh, Nibar Das, and Mita Nasipuri. Reshaping inputs for convolutional neural network: Some common and uncommon methods. *Pattern Recognition*, 93:79–94, 2019.
- [49] Balasubramanian Gopinath and Natesan Shanthi. Computer-aided diagnosis system for classifying benign and malignant thyroid nodules in multi-stained fnab cytological images. *Australasian physical & engineering sciences in medicine*, 36(2):219–230, 2013.
- [50] T Gregersen. Rapid method for distinction of gram-negative from gram-positive bacteria. *European journal of applied microbiology and biotechnology*, 5(2):123–127, 1978.
- [51] Tao Guan, Dongxiang Zhou, and Yunhui Liu. Accurate Segmentation of Partially Overlapping Cervical Cells Based on Dynamic Sparse Contour Searching and GVF Snake Model. *IEEE Journal of Biomedical and Health Informatics*, 19:1494–1504, 2015.
- [52] Yimo Guo, Guoying Zhao, and Matti Pietikäinen. Discriminative features for texture description. *Pattern Recognition*, 45(10):3834–3843, 2012.
- [53] A Peter Hall, Wendy Davies, Katie Stamp, Isabel Clamp, and Alison Bigley. Comparison of computerized image analysis with traditional semi-quantitative scoring of perls’ prussian blue stained hepatic iron deposition. *Toxicologic pathology*, 41(7):992–1000, 2013.

- [54] S L Happy, Swarnadip Chatterjee, and Debdoot Sheet. Unsupervised Segmentation of Overlapping Cervical Cell Cytoplasm. *CoRR*, abs/1505.0, 2015.
- [55] Robert M Haralick. *Pictorial data analysis*, volume 4. Springer Science & Business Media, 2012.
- [56] Negar M Harandi, Saeed Sadri, Noushin A Moghaddam, and Rassul Amirfattahi. An automated method for segmentation of epithelial cervical cells in images of ThinPrep. *Journal of medical systems*, 34(6):1043–1058, 12 2010.
- [57] J Holmquist, E Bengtsson, O Eriksson, B Nordin, and B Stenkvis. Computer analysis of cervical cells. Automatic feature extraction and classification. *Journal of Histochemistry & Cytochemistry*, 26(11):1000–1017, 11 1978.
- [58] Inc. Hologic. Thinprep ® imaging system operation summary and clinical information.
- [59] Md Shamim Hossain, Hamid A Jalab, Fariha Zulfiqar, and Mahfuza Pervin. Renal cancer cell nuclei detection from cytological images using convolutional neural network for estimating proliferation rate. *Journal of Telecommunication, Electronic and Computer Engineering (JTEC)*, 11(1):63–71, 2019.
- [60] Maciej Hrebień, Józef Korbicz, and Andrzej Obuchowicz. Hough transform, (1+1) search strategy and watershed algorithm in segmentation of cytological images. In M. Kurzynski, E. Puchala, M. Wozniak, and A. Zolnierek, editors, *Advances in Soft Computing*, volume 45, pages 550–557. Springer, Berlin, Heidelberg, 2007.
- [61] Maciej Hrebien, Piotr Stec, Tomasz Nieczkowski, and Andrzej Obuchowicz. Segmentation of Breast Cancer Fine Needle Biopsy Cytological Images. *Applied Mathematics and Computer Science*, 18:159–170, 2008.
- [62] Zilong Hu, Jinshan Tang, Ziming Wang, Kai Zhang, Lin Zhang, and Qingling Sun. Deep learning for image-based cancer detection and diagnosis A survey. *Pattern Recognition*, 83(11):134–149, 2018.
- [63] J Hyeon, H J Choi, B D Lee, and K N Lee. Diagnosing cervical cell images using pre-trained convolutional neural network as feature extractor. In *2017 IEEE International Conference on Big Data and Smart Computing (BigComp)*, pages 390–393, 2 2017.
- [64] Abdullah M. Ilyasu and Chastine Fatichah. A quantum hybrid PSO combined with fuzzy k-NN approach to feature selection and cell classification in cervical cancer detection. *Sensors (Switzerland)*, 17(12):1–17, 12 2017.

- [65] Indrabayu, A.R. Fatmasari, and Ingrid Nurtanio. A colour space based detection for cervical cancer using fuzzy C-means clustering. In *ACM International Conference Proceeding Series*, volume Part F1309, pages 137–141, 2017.
- [66] Nor Ashidi Mat Isa, Esugasini Subramaniam, Mohd Yusoff Mashor, and Nor Hayati Othman. Fine needle aspiration cytology evaluation for classifying breast cancer using artificial neural network. *American Journal of Applied Sciences*, 4(12):999–1008, 2007.
- [67] Z Islam and M A Haque. Multi-step level set method for segmentation of overlapping cervical cells. In *2015 IEEE International Conference on Telecommunications and Photonics (ICTP)*, pages 1–5, 2015.
- [68] S. Issac Niwas, P. Palanisamy, K. Sujathan, E. Bengtsson, S Issac Niwas, P. Palanisamy, K. Sujathan, and E. Bengtsson. Analysis of nuclei textures of fine needle aspirated cytology images for breast cancer diagnosis using Complex Daubechies wavelets. *Signal Processing*, 93(10):2828–2837, 2013.
- [69] Kourosh Jafari-Khouzani and Hamid Soltanian-Zadeh. Rotation-invariant multiresolution texture analysis using radon and wavelet transforms. *IEEE Transactions on Image Processing*, 14(6):783–795, 2005.
- [70] Lukasz Jeleń, Thomas Fevens, and Adam Krzyzak. Classification of Breast Cancer Malignancy Using Cytological Images of Fine Needle Aspiration Biopsies. *Int. J. Appl. Math. Comput. Sci.*, 18(1):75–83, 3 2008.
- [71] Lukasz Jelen, Thomas Fevens, Adam Krzyzak, ADAM KRZYZ AK ŁUKASZ JELEN, THOMAS FEVENS, Lukasz Jelen, Thomas Fevens, and Adam Krzyak. Classification of Breast Cancer Malignancy Using Cytological Images of Fine Needle Aspiration Biopsies. *Int. J. Appl. Math. Comput. Sci.*, 18(1):75–83, 3 2008.
- [72] Asli Kale and Selim Aksoy. Segmentation of cervical cell images. In *Proceedings - International Conference on Pattern Recognition*, pages 2399–2402, 2010.
- [73] K. Kancherla and S. Mukkamala. Early lung cancer detection using nucleus segmentation based features. In *2013 IEEE Symposium on Computational Intelligence in Bioinformatics and Computational Biology (CIBCB)*, pages 91–95, April 2013.
- [74] Michael Kass, Andrew Witkin, and Demetri Terzopoulos. Snakes: Active contour models. *International Journal of Computer Vision*, 1(4):321–331, 1 1988.
- [75] S. Sajith Kecheril, D. Venkataraman, J. Suganthi, and K. Sujathan. Automated lung cancer detection by the analysis of glandular cells in sputum cytology images using scale space features. *Signal, Image and Video Processing*, 9(4):851–863, 2015.

- [76] Roger A. Kemp, Daniel M. Reinders, and Bojana Turic. Detection of lung cancer by automated sputum cytometry. *Journal of Thoracic Oncology*, 2(11):993–1000, 2007.
- [77] Roger A Kemp, Daniel M Reinders, and Bojana Turic. Detection of lung cancer by automated sputum cytometry. *Journal of Thoracic Oncology*, 2(11):993–1000, 2007.
- [78] SanaUllah Khan, Naveed Islam, Zahoor Jan, Ikram Ud Din, and Joel JP C Rodrigues. A novel deep learning based framework for the detection and classification of breast cancer using transfer learning. *Pattern Recognition Letters*, 2019.
- [79] Kwang-Baek Kim, Sungshin Kim, and Gwang-Ha Kim. Nucleus Classification and Recognition of Uterine Cervical Pap-Smears Using FCM Clustering Algorithm. In Bartłomiej Beliczynski, Andrzej Dzielinski, Marcin Iwanowski, and Bernardete Ribeiro, editors, *Adaptive and Natural Computing Algorithms. ICANNGA 2007*, volume 4432, pages 290–299, Berlin, Heidelberg, 2007. Springer Berlin Heidelberg.
- [80] Leopold G Koss, Eunice Lin, Klaus Schreiber, Paul Elgert, and Laurie Mango. Evaluation of the papnetTM cytologic screening system for quality control of cervical smears. *American journal of clinical pathology*, 101(2):220–229, 1994.
- [81] M Kowal, M Żejmo, M Skobel, J Korbicz, and R Monczak. Cell nuclei segmentation in cytological images using convolutional neural network and seeded watershed algorithm. *Journal of digital imaging*, 2019.
- [82] Marek Kowal, Paweł Filipczuk, Andrzej Obuchowicz, and Józef Korbicz. Computer-aided diagnosis of breast cancer using Gaussian mixture cytological image segmentation. *Journal of medical informatics & Technologies*, 17:257–262, 2011.
- [83] P Kumar, S L Happy, S Chatterjee, D Sheet, and A Routray. An unsupervised approach for overlapping cervical cell cytoplasm segmentation. In *2016 IEEE EMBS Conference on Biomedical Engineering and Sciences (IECBES)*, pages 106–109, 2016.
- [84] Vineet Kumar and Hitesh Sharma. Extraction of Nuclear Region from Sputum Images through Pixel Classification for Early Lung Cancer Detection. *International Journal of Computer Applications*, 72(22):35–39, 6 2013.
- [85] Hansang Lee and Junmo Kim. Segmentation of Overlapping Cervical Cells in Microscopic Images with Superpixel Partitioning and Cell-Wise Contour Refinement. In *IEEE Computer Society Conference on Computer Vision and Pattern Recognition Workshops*, pages 1367–1373, 2016.

- [86] Kyoung-mi Lee and Nick Street. Generalized Hough Transforms with Flexible Templates. In *2000 International Conference on Artificial Intelligence (IC-AI'2000)*, pages 1133–1139, Las Vegas, 6 2000.
- [87] O. Lezoray and H. Cardot. Histogram and Watershed Based Segmentation of Color Images. In *European Conference on Colour in Graphics, Imaging and Vision (CGIV)*, pages 358–362, 2002.
- [88] Kuan Li, Zhi Lu, Wenyin Liu, and Jianping Yin. Cytoplasm and nucleus segmentation in cervical smear images using Radiating GVF Snake. *Pattern Recognition*, 45(4):1255–1264, 2012.
- [89] Yawu Li, Ning Li, Xiang Yu, Kai Huang, Ting Zheng, Xiaofeng Cheng, Shaoqun Zeng, and Xiuli Liu. Hematoxylin and eosin staining of intact tissues via delipidation and ultrasound. *Scientific reports*, 8(1):12259, 2018.
- [90] Chuen Horng Lin, Yung Kuan Chan, and Chun Chieh Chen. Detection and segmentation of cervical cell cytoplasm and nucleus. *International Journal of Imaging Systems and Technology*, 19(3):260–270, 2009.
- [91] Geert Litjens, Thijs Kooi, Babak Ehteshami Bejnordi, Arnaud Arindra Adiyoso Setio, Francesco Ciompi, Mohsen Ghafoorian, Jeroen A.W.M. van der Laak, Bram van Ginneken, and Clara I. Sánchez. A survey on deep learning in medical image analysis. *Medical Image Analysis*, 42(12):60–88, 2017.
- [92] Yiming Liu, Pengcheng Zhang, Qingche Song, Andi Li, Peng Zhang, and Zhiguo Gui. Automatic segmentation of cervical nuclei based on deep learning and a conditional random field. *IEEE Access*, 6:53709–53721, 2018.
- [93] P Lopes Cardozo. The significance of fine needle aspiration cytology for the diagnosis and treatment of malignant lymphomas. *Folia haematologica (Leipzig, Germany : 1928)*, 107(4):601–620, 1980.
- [94] Z Lu, G Carneiro, and A P Bradley. An Improved Joint Optimization of Multiple Level Set Functions for the Segmentation of Overlapping Cervical Cells. *IEEE Transactions on Image Processing*, 24(4):1261–1272, 2015.
- [95] Zhi Lu, Gustavo Carneiro, and Andrew P Bradley. Automated Nucleus and Cytoplasm Segmentation of Overlapping Cervical Cells. In Kensaku Mori, Ichiro Sakuma, Yoshinobu Sato, Christian Barillot, and Nassir Navab, editors, *Medical Image Computing and Computer-Assisted Intervention – MICCAI 2013*, pages 452–460, Berlin, Heidelberg, 2013. Springer Berlin Heidelberg.
- [96] M. Macenko, M. Niethammer, J. S. Marron, D. Borland, J. T. Woosley, Xiaojun Guan, C. Schmitt, and N. E. Thomas. A method for normalizing

- histology slides for quantitative analysis. In *2009 IEEE International Symposium on Biomedical Imaging: From Nano to Macro*, pages 1107–1110, June 2009.
- [97] Jihene Malek, Abderrahim Sebri, Souhir Mabrouk, Kholdoun Torki, and Rached Tourki. Automated Breast Cancer Diagnosis Based on GVF-Snake Segmentation, Wavelet Features Extraction and Fuzzy Classification. *J. Signal Process. Syst.*, 55(1-3):49–66, 4 2009.
- [98] Anita Mangia, Giulia Partipilo, Laura Schirosi, Concetta Saponaro, Domenico Galetta, Annamaria Catino, Anna Scattone, and Giovanni Simone. Fine Needle Aspiration Cytology: A Tool to Study NHERF1 Expression as a Potential Marker of Aggressiveness in Lung Cancer. *Molecular Biotechnology*, 57(6):549–557, 2015.
- [99] Edwin Jayasingh Mariarputham and Allwin Stephen. Nominated Texture Based Cervical Cancer Classification. *Computational and Mathematical Methods in Medicine*, 2015:1–10, 1 2015.
- [100] Shahla Masood, Dian Feng, Osman Tutuncuoglu, Gabor Fischer, Maryam Bakhshandeh, Roger L. Bertholf, and David Wolfson. Diagnostic value of imprint cytology during image-guided core biopsy in improving breast health care. *Annals of Clinical and Laboratory Science*, 41(1):8–13, 2011.
- [101] N A Mat-Isa and Nor Ashidi Mat Isa. Automated edge detection technique for Pap smear images using moving K-means clustering and modified seed based region growing algorithm. *International Journal of the Computer, the Internet and Management*, 13(3):45–59, 1 2005.
- [102] Nor Ashidi Mat-Isa, Mohd Yusoff Mashor, and Nor Hayati Othman. An automated cervical pre-cancerous diagnostic system. *Artificial Intelligence in Medicine*, 42(1):1–11, 2008.
- [103] B Mehdi, D Stacey, and G Harauz. A Hierarchical Neural-Network Assembly For Classification Of Cervical Cells In Automated Screening. *Analytical Cellular Pathology*, 7(3):171–180, 1994.
- [104] Xu Meiquan, Zeng Weixiu, Sun Yanhua, Wu Junhui, Wu Tingting, Yang Yajie, Zhang Meng, Zhu Zeji, and Chen Longsen. Cervical cytology intelligent diagnosis based on object detection technology. 2018.
- [105] Shyamali Mitra, Soumyajyoti Dey, Nibaran Das, Sukanta Chakrabarty, Mita Nasipuri, and Mrinal Kanti Naskar. Identification of Benign and Malignant Cells from Cytological Images Using Superpixel Based Segmentation Approach. In Jyotsna Kumar Mandal and Devadatta Sinha, editors, *52nd Annual Convention of CSI 2018: Social Transformation – Digital Way*, pages 257–269, Singapore, 2018. Springer Singapore.

- [106] T Mouroutis, S J Roberts, A A Bharath, and G Alusi. Compact {Hough} {Transform} and a maximum likelihood approach to cell nuclei detection. *Proceedings of 13th International Conference on Digital Signal Processing*, 2:869–872, 1997.
- [107] Theodoros Mouroutis, Stephen J. Roberts, and Anil A. Bharath. Robust cell nuclei segmentation using statistical modelling. *Bioimaging*, 6(2):79–91, 1998.
- [108] Izzati Muhimmah, Rahadian Kurniawan, and Indrayanti. Automated cervical cell nuclei segmentation using morphological operation and watershed transformation. In *Proceeding - 2012 IEEE International Conference on Computational Intelligence and Cybernetics, CyberneticsCom 2012*, pages 163–167, 2012.
- [109] N Mustafa, N A M Isa, M Y Mashor, and N H Othman. Colour Contrast Enhancement on Preselected Cervical Cell for ThinPrep® Images. In *Third International Conference on Intelligent Information Hiding and Multimedia Signal Processing (IIH-MSP 2007)*, volume 2, pages 209–212, 2007.
- [110] L Na and L Jian-Xin. Automatic Color Image Segmentation Based on Anisotropic Diffusion and the Application in Cancer Cell Segmentation. In *2007 1st International Conference on Bioinformatics and Biomedical Engineering*, pages 992–994, 2007.
- [111] Nephron, 2010.
- [112] Nephron, 2010.
- [113] Nephron, 2010.
- [114] Nephron, 2015.
- [115] Nephron, 2016.
- [116] S.I. Niwas, P. Palanisamy, and K. Sujathan. Wavelet based feature extraction method for breast cancer cytology images. *Industrial Electronics & Applications (ISIEA), 2010 IEEE Symposium on*, (Isiea):686–690, 2010.
- [117] Yoshiaki Norimatsu, Shingo Sakamoto, Hiroyuki Ohsaki, Satoru Ozaki, Toshiro Yokoyama, Keiko Shimizu, Kenji Yanoh, Minoru Akiyama, Masamichi Bamba, and Tadao K Kobayashi. Cytologic features of the endometrial adenocarcinoma: comparison of thinprep and bd surepath preparations. *Diagnostic cytopathology*, 41(8):673–681, 2013.
- [118] M S Nosrati and G Hamarneh. Segmentation of overlapping cervical cells: A variational method with star-shape prior. In *2015 IEEE 12th International Symposium on Biomedical Imaging (ISBI)*, pages 186–189, 4 2015.

- [119] T Ojala, M Pietikainen, and T Maenpaa. Multiresolution gray-scale and rotation invariant texture classification with local binary patterns. *Pattern Analysis and Machine Intelligence, IEEE Transactions on*, 24(7):971–987, 2002.
- [120] M. Orozco-Monteagudo, T. Geerinck, C. Mihai, H. Sahli, and A. Taboada-Crispi. Pap-smear cell nucleus extraction by using morphological watershed. In *IFMBE Proceedings*, volume 33 IFMBE, pages 1070–1073, 2013.
- [121] Maykel Orozco-Monteagudo, Cosmin Mihai, Hichem Sahli, and Alberto Taboada-Crispi. Combined hierarchical watershed segmentation and SVM classification for pap smear cell nucleus extraction. In *Computacion y Sistemas*, volume 16, pages 133–145, 2012.
- [122] P S Oud, D J Zahniser, R Harbers-Hendriks, M C van Boekel, M C Raaijmakers, and P G Vooijs. The development of a cervical smear preparation procedure from the BioPEPR image analysis system. *Analytical and quantitative cytology*, 3(1):73–79, 3 1981.
- [123] Pei Yan Pai, Chin Chen Chang, and Yung Kuan Chan. Nucleus and cytoplasm contour detector from a cervical smear image. *Expert Systems with Applications*, 39(1):154–161, 2012.
- [124] Jürgen Pannek, Franziska Rademacher, and Jens Wöllner. Clinical usefulness of urine cytology in the detection of bladder tumors in patients with neurogenic lower urinary tract dysfunction. *Research and reports in urology*, 9:219, 2017.
- [125] Liron Pantanowitz and Anil V Parwani. *Practical informatics for cytopathology*. Springer, 2014.
- [126] Hady Ahmady Phoulady and Peter R Mouton. A new cervical cytology dataset for nucleus detection and image classification (cervix93) and methods for cervical nucleus detection. *arXiv preprint arXiv:1811.09651*, 2018.
- [127] M E Plissiti, C Nikou, and A Charchanti. Automated Detection of Cell Nuclei in Pap Smear Images Using Morphological Reconstruction and Clustering. *Trans. Info. Tech. Biomed.*, 15(2):233–241, 3 2011.
- [128] Marina E Plissiti, Christophoros Nikou, and Antonia Charchanti. Combining shape, texture and intensity features for cell nuclei extraction in Pap smear images. *Pattern Recognition Letters*, 32(6):838–853, 2011.
- [129] Marina E Plissiti, Christophoros Nikou, and Senior Member. Overlapping Cell Nuclei Segmentation Using a Spatially Adaptive Active Physical Model. *IEEE Transactions on Image Processing*, 21(11):4568–4580, 2012.

- [130] Marina E. Plissiti, Michalis Vrigkas, and Christophoros Nikou. Segmentation of cell clusters in Pap smear images using intensity variation between superpixels. In *2015 22nd International Conference on Systems, Signals and Image Processing - Proceedings of IWSSIP 2015*, pages 184–187, 2015.
- [131] S Rachid, N Niki, H Nishitani, S Nakamura, and S Mori. Segmentation of sputum color image for lung cancer diagnosis. In *Proceedings of International Conference on Image Processing*, volume 1, pages 243–246, 1997.
- [132] S Ragothaman, S Narasimhan, M G Basavaraj, and R Dewar. Unsupervised Segmentation of Cervical Cell Images Using Gaussian Mixture Model. In *2016 IEEE Conference on Computer Vision and Pattern Recognition Workshops (CVPRW)*, pages 1374–1379, 6 2016.
- [133] Rahmadwati, Golshah Naghdy, Montserrat Ros, Catherine Todd, and Eviana Norahmawati. Cervical Cancer Classification Using Gabor Filters. In *IEEE First International Conference on Healthcare Informatics, Imaging and Systems Biology*, pages 48–52. IEEE, 2011.
- [134] JL Ramirez-Zacarias, F Castro-Munozledo, and W Kuri-Harcuch. Quantitation of adipose conversion and triglycerides by staining intracytoplasmic lipids with oil red o. *Histochemistry*, 97(6):493–497, 1992.
- [135] D.A. Ramli, A.F. Kadmin, M.Y. Mashor, and Nor Ashidi Mat Isa. Diagnosis of cervical cancer using hybrid multilayered perceptron (HMLP) network. In *Lecture Notes in Computer Science*, volume 3213, pages 591–598. 2004.
- [136] Motoyasu Sagawa, Katsuo Usuda, Hirokazu Aikawa, Makoto Tanaka, Yuichiro Machida, Masakatsu Ueno, and Tsutomu Sakuma. [Screening for lung cancer: present and future]. *Gan to kagaku ryoho. Cancer & chemotherapy*, 39(1):19–22, 2012.
- [137] Monjoy Saha, Rashmi Mukherjee, and Chandan Chakraborty. Computer-aided diagnosis of breast cancer using cytological images: A systematic review. *Tissue and Cell*, 48(5):461–474, 2016.
- [138] Ratna Saha, Mariusz Bajger, and Gobert Lee. Spatial Shape Constrained Fuzzy C-Means (FCM) Clustering for Nucleus Segmentation in Pap Smear Images. In *International Conference on Digital Image Computing: Techniques and Applications (DICTA-16)*, pages 1–8, Gold Coast, QLD, Australia, 11 2016.
- [139] Amartya Ranjan Saikia, Kangkana Bora, Lipi B Mahanta, and Anup Kumar Das. Comparative assessment of cnn architectures for classification of breast fnac images. *Tissue and Cell*, 57:8–14, 2019.

- [140] T. A. Sajeena and A. S. Jereesh. Cervical cancer detection through automatic segmentation and classification of Pap smear cells. *International Journal of Applied Engineering Research*, 10(18):39078–39084, 9 2015.
- [141] Rachid Sammouda, Noboru Niki, Hiromu Nishitani, and Emi Kyokage. Segmentation of Sputum Color Image for Lung Cancer Diagnosis based on Neural Network. *IEICE TRANSACTIONS on Information and Systems*, E81-D(8):862–871, 1998.
- [142] Parikshit Sanyal, Tanushri Mukherjee, Sanghita Barui, Avinash Das, and Prabaha Gangopadhyay. Artificial intelligence in cytopathology: A neural network to identify papillary carcinoma on thyroid fine-needle aspiration cytology smears. *Journal of pathology informatics*, 9, 2018.
- [143] Dharmesh A Sarvaiya and Mehul Barot. Detection of Lung Cancer using Sputum Image Segmentation. *International Journal of Advance Engineering and Research Development (IJAERD)*, 1(6):1–9, 2014.
- [144] L. Shajy, Varghese Paul, P. Marichamy, and K. Sujathan. Analysis of Textures of Sputum Cytology Images for Lung Cancer Diagnosis using Discrete Wavelets Transform. *International Journal of Applied Engineering Research*, 10(4):9217–9229, 1 2015.
- [145] Howard M Shapiro. The evolution of cytometers. *Cytometry part A*, 58(1):13–20, 2004.
- [146] B Sharma and K K Mangat. An improved nucleus segmentation for cervical cell images using FCM clustering and BPNN. In *2016 International Conference on Advances in Computing, Communications and Informatics (ICACCI)*, pages 1924–1929, 2016.
- [147] Sanjay Kumar Singh and Anjali Goyal. A Novel Approach to Segment Nucleus of Uterine Cervix Pap Smear Cells Using Watershed Segmentation. In Dharm Singh, Balasubramanian Raman, Ashish Kumar Luhach, and Pawan Lingras, editors, *Advanced Informatics for Computing Research*, pages 164–174, Singapore, 2017. Springer Singapore.
- [148] S.Anantha Sivaprakasam and E.R.Naganathan. SEGMENTATION AND CLASSIFICATION OF CERVICAL CYTOLOGY IMAGES USING MORPHOLOGICAL AND STATISTICAL OPERATIONS. *ICTACT JOURNAL ON IMAGE AND VIDEO PROCESSING*, 07:1445–1455, 2017.
- [149] Y Song, E L Tan, X Jiang, J Z Cheng, D Ni, S Chen, B Lei, and T Wang. Accurate Cervical Cell Segmentation from Overlapping Clumps in Pap Smear Images. *IEEE Transactions on Medical Imaging*, 36(1):288–300, 1 2017.

- [150] Youyi Song, Ling Zhang, Siping Chen, Dong Ni, Baiying Lei, and Tianfu Wang. Accurate segmentation of cervical cytoplasm and nuclei based on multiscale convolutional network and graph partitioning. *IEEE Transactions on Biomedical Engineering*, 62(10):2421–2433, 2015.
- [151] Youyi Song, Ling Zhang, Siping Chen, Dong Ni, Baopu Li, Yongjing Zhou, Baiying Lei, and Tianfu Wang. A deep learning based framework for accurate segmentation of cervical cytoplasm and nuclei. In *2014 36th Annual International Conference of the IEEE Engineering in Medicine and Biology Society*, pages 2903–2906. IEEE, 2014.
- [152] Y Srinivasan, B Nutter, S Mitra, B Phillips, and E Sinzinger. Classification of Cervix Lesions Using Filter Bank-Based Texture Mode. In *19th IEEE Symposium on Computer-Based Medical Systems (CBMS'06)*, pages 832–840, 2006.
- [153] W N Street. Xcyt: a System for Remote Cytological Diagnosis and Prognosis of Breast Cancer. In *Artificial Intelligence Techniques in Breast Cancer Diagnosis and Prognosis*, volume 39 of *Series in Machine Perception and Artificial Intelligence*, pages 297–326. World Scientific Publishing Co., 8 2000.
- [154] William N Street. Xcyt: A system for remote cytological diagnosis and prognosis of breast cancer. *SERIES IN MACHINE PERCEPTION AND ARTIFICIAL INTELLIGENCE*, 39:297–326, 2000.
- [155] P. Sukumar and R.K. K. Gnanamurthy. Computer aided detection of cervical cancer using pap smear images based on adaptive neuro fuzzy inference system classifier. *Journal of Medical Imaging and Health Informatics*, 6(2):312–319, 2016.
- [156] Ali Tabesh, Mikhail Teverovskiy, Ho Yuen Pang, Vinay P. Kumar, David Verbel, Angeliki Kotsianti, and Olivier Saidi. Multifeature prostate cancer diagnosis and gleason grading of histological images. *IEEE Transactions on Medical Imaging*, 26(10):1366–1378, 2007.
- [157] Bilal Taha, Jorge Dias, and Naoufel Werghi. Classification of Cervical-Cancer Using Pap-Smear Images: A Convolutional Neural Network Approach. In María Valdés Hernández and Víctor González-Castro, editors, *Medical Image Understanding and Analysis*, pages 261–272, Cham, 2017. Springer International Publishing.
- [158] F Taher and R Sammouda. Identification of Lung Cancer Based on Shape and Color. In *2007 Innovations in Information Technologies (IIT)*, pages 481–485, 2007.
- [159] F Taher, N Werghi, and H Al-Ahmad. Bayesian classification and artificial neural network methods for lung cancer early diagnosis. In *2012 19th IEEE International Conference on Electronics, Circuits, and Systems (ICECS 2012)*, pages 773–776, 2012.

- [160] F Taher, N Werghi, and H Al-Ahmad. Computer aided diagnosis system for early lung cancer detection. In *2015 International Conference on Systems, Signals and Image Processing (IWSSIP)*, pages 5–8, 9 2015.
- [161] Fatma Taher, Rachid Sammouda, Fatma Taher, and Rachid Sammouda. Artificial Neural Network and Fuzzy Clustering Methods in Segmenting Sputum Color Images for Lung Cancer Diagnosis. In Abderrahim Elmoataz, Olivier Lezoray, Fathallah Nouboud, Driss Mammass, and Jean Meunier, editors, *Image and Signal Processing*, volume 3, pages 513–520, Berlin, Heidelberg, 2010. Springer Berlin Heidelberg.
- [162] Noboru Tanaka, Hideo Ikeda, Tetsuo Ueno, Akio Mukawa, Sadakazu Watanabe, Kozo Okamoto, Sugao Hosoi, and Sho Tsunekawa. Automated cytologic screening system (cybest model 4): an integrated image cytometry system. *Applied optics*, 26(16):3301–3307, 1987.
- [163] J R Tang, N A M Isa, and E S Ch’ng. Segmentation of cervical cell nucleus using Intersecting Cortical Model optimized by Particle Swarm Optimization. In *2015 IEEE International Conference on Control System, Computing and Engineering (ICCSCE)*, pages 111–116, 11 2015.
- [164] A Tareef, Y Song, M Z Lee, D D Feng, M Chen, and W Cai. Morphological Filtering and Hierarchical Deformation for Partially Overlapping Cell Segmentation. In *2015 International Conference on Digital Image Computing: Techniques and Applications (DICTA)*, pages 1–7, 11 2015.
- [165] Afaf Tareef, Yang Song, Heng Huang, Yue Wang, Dagan Feng, Mei Chen, and Weidong Cai. Optimizing the cervix cytological examination based on deep learning and dynamic shape modeling. *Neurocomputing*, 248:28–40, 2017.
- [166] Atsushi Teramoto, Tetsuya Tsukamoto, Yuka Kiriya, and Hiroshi Fujita. Automated Classification of Lung Cancer Types from Cytological Images Using Deep Convolutional Neural Networks. *BioMed Research International*, 2017:1–6, 2017.
- [167] Walter E. Tolles. The cytoanalyzer-an example of physics in medical research. *Transactions of the New York Academy of Sciences*, 17 3:250–6, 1955.
- [168] Meng-Husiu Tsai, Yung-Kuan Chan, Zhe-Zheng Lin, Shys-Fan Yang-Mao, and Po-Chi Huang. Nucleus and Cytoplasm Contour Detector of Cervical Smear Image. *Pattern Recogn. Lett.*, 29(9):1441–1453, 7 2008.
- [169] J. H. Tucker. Cerviscan: An image analysis system for experiments in automatic cervical smear prescreening. *Computers and Biomedical Research*, 9(2):93–107, 1976.

- [170] JH Tucker. Cerviscan: An image analysis system for experiments in automatic cervical smear prescreening. *Computers and Biomedical Research*, 9(2):93–107, 1976.
- [171] Daniela M Ushizima, Andrea Gomes Campos Bianchi, and Claudia M Carneiro. Segmentation of Subcellular Compartments Combining Superpixel Representation with Voronoi Diagrams. In *Overlapping Cervical Cytology Image Segmentation Challenge - IEEE ISBI*, pages 1–2, 2014.
- [172] Ed Uthman, 2010.
- [173] Philip T Valente and H Daniel Schantz. Cytology automation: An overview. *Laboratory medicine*, 32(11):686–690, 2001.
- [174] R.F Walker. *Adaptive multi-scale texture analysis with application to automated cytology*. PhD thesis, University of Queensland, 1997.
- [175] ML Warnock, A Stoloff, and A Thor. Differentiation of adenocarcinoma of the lung from mesothelioma. periodic acid-schiff, monoclonal antibodies b72. 3, and leu m1. *The American journal of pathology*, 133(1):30, 1988.
- [176] Sadakazu Watanabe. An automated apparatus for cancer prescreening: CYBEST. *Computer Graphics and Image Processing*, 3(4):350–358, 1974.
- [177] N Werghi, C Donner, F Taher, and H Al-Ahmad. Detection and segmentation of sputum cell for early lung cancer detection. In *2012 19th IEEE International Conference on Image Processing*, pages 2813–2816, 2012.
- [178] B Weyn, G van de Wouwer, A van Daele, P Scheunders, D van Dyck, E van Marck, and W Jacob. Automated breast tumor diagnosis and grading based on wavelet chromatin texture description. *Cytometry*, 33(1):32–40, 9 1998.
- [179] WHO. Who(world health organization) report, 2018.
- [180] D C Wilbur. Digital Cytology: Current State of the Art and Prospects for the Future. *Acta Cytologica*, 55(3):227–238, 2011.
- [181] Wasswa William, Andrew Ware, Annabella Habinka Basaza-Ejiri, and Johnes Obungoloch. A review of image analysis and machine learning techniques for automated cervical cancer screening from pap-smear images. *Computer Methods and Programs in Biomedicine*, 164:15–22, 2018.
- [182] DH Wittekind. On the nature of romanowsky-giemasa staining and its significance for cytochemistry and histochemistry: an overall view. *The Histochemical Journal*, 15(10):1029–1047, 1983.
- [183] W. H. Wolberg and O. L. Mangasarian. Multisurface method of pattern separation for medical diagnosis applied to breast cytology. *Proceedings of the National Academy of Sciences*, 87(23):9193–9196, 1990.

- [184] W H Wolberg, W N Street, and O L Mangasarian. Breast cytology diagnosis with digital image analysis. *Analytical and quantitative cytology and histology / the International Academy of Cytology [and] American Society of Cytology*, 15(6):396–404, 1993.
- [185] W H Wolberg, W N Street, and O L Mangasarian. Image-Analysis and Machine Learning Applied to Breast-Cancer Diagnosis and Prognosis. *Analytical and Quantitative Cytology and Histology*, 17(2):77–87, 1995.
- [186] William H. Wolberg, W.Nick Nick Street, and O. L. Mangasarian. Machine learning techniques to diagnose breast cancer from image-processed nuclear features of fine needle aspirates. *Cancer Letters*, 77(2):163–171, 1994.
- [187] Miao Wu, Chuanbo Yan, Huiqiang Liu, and Qian Liu. Automatic classification of ovarian cancer types from cytological images using deep convolutional neural networks. *Bioscience Reports*, 38(3):1–7, 2018.
- [188] Miao Wu, Chuanbo Yan, Huiqiang Liu, Qian Liu, and Yi Yin. Automatic classification of cervical cancer from cytological images by using convolutional neural network. *Bioscience reports*, 38(6):BSR20181769, 2018.
- [189] Xuqing Wu, Mojgan Amrikachi, and Shishir K. Shah. Embedding topic discovery in conditional random fields model for segmenting nuclei using multispectral data. *IEEE Transactions on Biomedical Engineering*, 59(6):1539–1549, 2012.
- [190] Xuqing Wu and Shishir K Shah. Cell segmentation in multispectral images using level sets with priors for accurate shape recovery. *Biomedical Imaging: From Nano to Macro, 2011 IEEE International Symposium on*, pages 2117–2120, 2011.
- [191] Xuqing Wu, James Thigpen, and Shishir K Shah. Multispectral microscopy and cell segmentation for analysis of thyroid fine needle aspiration cytology smears. In *2009 Annual International Conference of the IEEE Engineering in Medicine and Biology Society*, pages 5645–5648. IEEE, 2009.
- [192] Chenyang Xu and Jerry L. Prince. Snakes, shapes, and gradient vector flow. *IEEE Transactions on Image Processing*, 7(3):359–369, 1998.
- [193] Jian Yang and Yikai Zhou. Detection of DNA aneuploidy in exfoliated airway epithelia cells of sputum specimens by the automated image cytometry and its clinical value in the identification of lung cancer. *Journal of Huazhong University of Science and Technology. Medical sciences = Hua zhong ke ji da xue xue bao. Yi xue Ying De wen ban = Huazhong keji daxue xuebao. Yixue Yingdewen ban*, 24(4):407–10, 2004.

- [194] Lin Yang, Peter Meer, and David J. Foran. Unsupervised segmentation based on robust estimation and color active contour models. *IEEE Transactions on Information Technology in Biomedicine*, 9(3):475–486, 2005.
- [195] Xiaodong Yang, Houqiang Li, and Xiaobo Zhou. Nuclei segmentation using marker-controlled watershed, tracking using mean-shift, and Kalman filter in time-lapse microscopy. *IEEE Transactions on Circuits and Systems I: Regular Papers*, 53(11):2405–2414, 2006.
- [196] Shys Fan Yang-Mao, Yung Kuan Chan, and Yen Ping Chu. Edge enhancement nucleus and cytoplasm contour detector of cervical smear images. *IEEE Transactions on Systems, Man, and Cybernetics, Part B: Cybernetics*, 38(2):353–366, 2008.
- [197] D. J. Zahniser, P. S. Oud, M. C.T. Raaijmakers, G. P. Vooy, and R. T. Van de Walle. BioPEPR: A system for the automatic prescreening of cervical smears. *Journal of Histochemistry and Cytochemistry*, 27(1):635–641, 1979.
- [198] David J. Zahniser and Anne A. Hurley. Automated slide preparation system for the clinical laboratory. *Communications in Clinical Cytometry*, 26(1):60–64, 9 1996.
- [199] Michał Żejmo, Marek Kowal, Józef Korbicz, and Roman Monczak. Classification of breast cancer cytological specimen using convolutional neural network. : *Journal of Physics: Conf. Series*, 783(012060):1–11, 2017.
- [200] Ziming Zeng, Siping Chen, Sheng Tang, and Lidong Yin. Unsupervised segmentation of cell nuclei in cervical smear images using active contour with adaptive local region fitting energy modelling. In *Proceedings - 2015 8th International Conference on BioMedical Engineering and Informatics, BMEI 2015*, pages 250–254, 2016.
- [201] J Y Zhang and Y X Liu. Cervical cancer detection using SVM based feature screening. In Christian Barillot, David R Haynor, and Pierre Hellier, editors, *International Conference on Medical Image Computing and Computer-Assisted Intervention 2004*, volume 3217, pages 873–880, Berlin, Heidelberg, 2004. Springer Berlin Heidelberg.
- [202] L Zhang, H Kong, C T Chin, S Liu, T Wang, and S Chen. Automated segmentation of abnormal cervical cells using global and local graph cuts. In *2014 IEEE 11th International Symposium on Biomedical Imaging (ISBI)*, pages 485–488, 2014.
- [203] Ling Zhang, Siping Chen, Tianfu Wang, Yan Chen, Shaoxiong Liu, and Minghua Li. A Practical Segmentation Method for Automated Screening of Cervical Cytology. In *International Conference on Intelligent Computation and Bio-Medical Instrumentation*, pages 140–143. IEEE, 2011.

- [204] Ling Zhang, Hui Kong, Chien Ting Chin, Shaoxiong Liu, Zhi Chen, Tianfu Wang, and Siping Chen. Segmentation of cytoplasm and nuclei of abnormal cells in cervical cytology using global and local graph cuts. *Computerized Medical Imaging and Graphics*, 38(5):369–380, 2014.
- [205] Ling Zhang, Hui Kong, Shaoxiong Liu, Tianfu Wang, Siping Chen, and Milan Sonka. Graph-based segmentation of abnormal nuclei in cervical cytology. *Computerized medical imaging and graphics : the official journal of the Computerized Medical Imaging Society*, 56:38–48, 3 2017.
- [206] Ling Zhang, Le Lu, Isabella Nogues, Ronald M. Summers, Shaoxiong Liu, and Jianhua Yao. DeepPap: Deep convolutional networks for cervical cell classification. *IEEE Journal of Biomedical and Health Informatics*, 21(6):1633–1643, 2017.
- [207] Lili Zhao, Kuan Li, Mao Wang, Jianping Yin, En Zhu, Chengkun Wu, Siqi Wang, and Chengzhang Zhu. Automatic cytoplasm and nuclei segmentation for color cervical smear image using an efficient gap-search MRF. *Computers in Biology and Medicine*, 71:46–56, 2016.