

# Deep Multi-Magnification Networks for Multi-Class Breast Cancer Image Segmentation

David Joon Ho<sup>a,\*</sup>, Dig V. K. Yarlagadda<sup>a</sup>, Timothy M. D'Alfonso<sup>a</sup>, Matthew G. Hanna<sup>a</sup>, Anne Grabenstetter<sup>a</sup>, Peter Ntiamoah<sup>a</sup>, Edi Brogi<sup>a</sup>, Lee K. Tan<sup>a</sup>, Thomas J. Fuchs<sup>a,b</sup>

<sup>a</sup>*Department of Pathology, Memorial Sloan Kettering Cancer Center, New York, NY 10065 USA*

<sup>b</sup>*Weill Cornell Graduate School for Medical Sciences, New York, NY 10065 USA*

---

## Abstract

Pathologic analysis of surgical excision specimens for breast carcinoma is important to evaluate the completeness of surgical excision and has implications for future treatment. This analysis is performed manually by pathologists reviewing histologic slides prepared from formalin-fixed tissue. In this paper, we present Deep Multi-Magnification Network trained by partial annotation for automated multi-class tissue segmentation by a set of patches from multiple magnifications in digitized whole slide images. Our proposed architecture with multi-encoder, multi-decoder, and multi-concatenation outperforms other single and multi-magnification-based architectures by achieving the highest mean intersection-over-union, and can be used to facilitate pathologists' assessments of breast cancer.

*Keywords:* Breast Cancer, Computational Pathology, Multi-Class Image Segmentation, Deep Multi-Magnification Network, Partial Annotation

---

## 1. Introduction

Breast carcinoma is the most common cancer to be diagnosed for women [1]. Approximately 12% of women in the United States will be diagnosed with

---

\*Corresponding author  
Email address: [hod@mskcc.org](mailto:hod@mskcc.org) (David Joon Ho)

breast cancer during their lifetime [2]. Pathologists diagnose breast carcinoma based on a variety of morphologic features including tumor growth pattern and nuclear cytologic features. Pathologic assessment of breast tissue dictates the clinical management of the patient and provides prognostic information. Breast tissue from a variety of biopsies and surgical specimens is evaluated by pathologists. For example, patients with early-stage breast cancer often undergo breast-conserving surgery, or lumpectomy, which removes a portion of breast tissue containing the cancer [3]. To determine the completeness of the surgical excision, the edges of the lumpectomy specimen, or margins, are evaluated microscopically by a pathologist. Achieving negative margins (no cancer found touching the margins) is important to minimize the risk of local recurrence of the cancer [4]. Accurate analysis of margins by the pathologist is critical for determining the need for additional surgery. Pathologic analysis of margin specimens involves the pathologist reviewing roughly 20-40 histologic slides per case, and this process can be time-consuming and tedious. With the increasing capabilities of digitally scanning histologic glass slides, computational pathology approaches could potentially improve the efficiency and accuracy of this process by evaluating whole slide images (WSIs) of specimens [5].

Various approaches have been used to analyze WSIs. Most models include localization, detection, classification, and segmentation of objects (i.e. histologic features) in digital slides. Histopathologic features include pattern-based identification, such as nuclear features, cellular/stromal architecture, or texture. Computational pathology has been used in nuclei segmentation to extract nuclear features such as size, shape, and relationship between them [6, 7]. Nuclei segmentation is done by adaptive thresholding and morphological operations to find regions where nuclei density is high [8]. A breast cancer grading method can be developed by gland and nuclei segmentation using a Bayesian classifier and structural constraints from domain knowledge [9]. To segment overlapping nuclei and lymphocytes, an integrated active contour based on region, boundary, and shape is presented in [10]. A gland segmentation and classification method in prostate tissue is introduced where structural and contextual fea-

tures from nuclei, cytoplasm, and lumen are used to classify artifact, normal gland, and cancer gland [11]. These nuclei-segmentation-based approaches are challenging because shapes of nuclei and structures of cancer regions may have large variations in the tissue samples captured in the WSIs.

Recently, deep learning, a type of machine learning, has been widely used for automatic image analysis due to the availability of large training datasets and the advancement of graphics processing units (GPUs) [12]. Deep learning models composed of deep layers with non-linear activation functions enable to learn more sophisticated features. Especially, convolutional neural networks (CNNs) learning spatial features in images have shown outstanding achievements in image classification [13], object detection [14], and semantic segmentation [15]. Fully Convolutional Network (FCN) in [15] developed for semantic segmentation, also known as pixel-wise classification, can understand location, size, and shape of objects in images. FCN is composed of an encoder and a decoder, where the encoder extracts low-dimensional features of an input image and the decoder utilizes the low-dimensional features to produce segmentation predictions. To improve segmentation predictions, SegNet introduces max-unpooling layers where max-pooling indices in an encoder are stored and used at the corresponding upsampling layers in a decoder [16]. Semantic segmentation has been used on medical images to automatically segment biological structures. For example, U-Net [17] is used to segment cells in microscopy images. U-Net architecture has concatenations transferring feature maps from an encoder to a decoder to preserve spatial information. This architecture has shown more precise segmentation predictions on biomedical images.

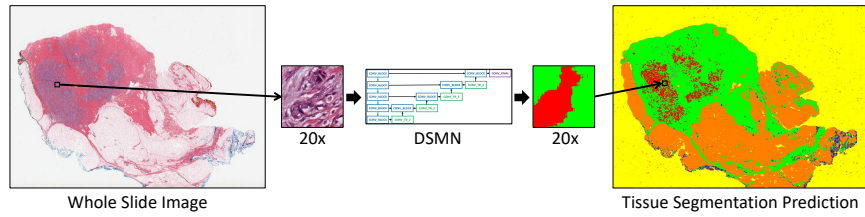
Deep learning has recently received high attention in the computational pathology community [18, 19, 20]. Investigators have shown automated identification of invasive breast cancer detection in WSIs by using a simple 3-layer CNN [21]. A method of classifying breast tissue slides to invasive cancer or benign by analyzing stroma regions using CNNs is described in [22]. More recently, a multiple-instance-learning-based CNN achieves 100% sensitivity where the CNN is trained by 44,732 WSIs from 15,187 patients [23]. The availability of public

pathology datasets contributes to develop many deep learning approaches for computational pathology. For example, a breast cancer dataset to detect lymph node metastases was released for the CAMELYON challenges [24, 25] and several deep learning techniques to analyze breast cancer datasets are developed [26, 27, 28].

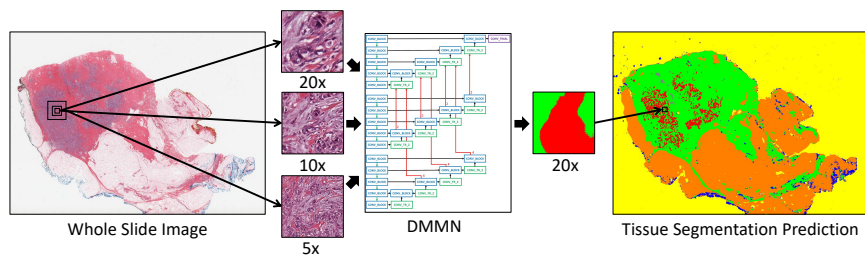
One challenge of using deep learning on WSIs is that the size of a single, entire WSI is too large to be processed into GPUs. Images can be downsampled to be processed by pretrained CNNs [29, 30] but critical details needed for clinical diagnosis in WSIs would be lost. To solve this, patch-based approaches are generally used instead of slide-level approaches. Here, patches are extracted from WSIs to be processed by CNNs. A patch-based process followed by a multi-class logistic regression to classify in slide-level is described in [31]. The winner of the CAMELYON16 challenge uses the Otsu thresholding technique [32] to extract tissue regions and trains a patch-based model to classify tumor and non-tumor patches [26]. To increase the performance, class balancing between tumor and non-tumor patches and data augmentation techniques such as rotation, flip, and color jittering are used in [27]. The winner of the CAMELYON17 challenge additionally develops patch-overlapping strategy for more accurate predictions [28]. In [33], a patch is processed with an additional larger patch including border regions in the same magnification to segment subtypes in breast WSIs. Alternatively, Representation-Aggregation CNNs to aggregate features generated from patches in WSIs are developed to share representations between patches [34, 35]. The main limitations of these patch-based approaches extracted from a single magnification are (1) the field-of-view becomes narrow and (2) morphological features from a lower magnification are not used.

Therefore, we develop segmentation CNNs by inputting a set of patches from multiple magnifications to increase the field-of-view and to provide more information from other magnifications. Figure 1 introduces the main difference between a Deep Single-Magnification Network (DSMN) and a Deep Multi-Magnification Network (DMMN) for tissue segmentation of whole slide images. An input to a DSMN in Figure 1(a) is a patch from a single magnification which





(a) Deep Single-Magnification Network



(b) Deep Multi-Magnification Network

Figure 1: Introduction of a Deep Single-Magnification Network (DSMN) and a Deep Multi-Magnification Network (DMMN) for tissue segmentation of whole slide images. (a) A DSMN looks at a patch from a single magnification from a whole slide image with limited field-of-view to generate the corresponding multi-class tissue segmentation prediction. (b) A DMMN looks at a set of patches from multiple magnifications from a whole slide image to have wider field-of-view to generate the corresponding multi-class tissue segmentation prediction. The DMMN can learn both cellular features from a higher magnification and architectural growth patterns from a lower magnification. Here, carcinoma is predicted in red, benign epithelial in blue, background in yellow, stroma in green, necrotic in gray, and adipose in orange.

limits a field-of-view. An input to a DMMN in Figure 1(b) is a set of patches from multiple magnifications allowing a wider field-of-view. High magnification patches provide details at the cellular level, such as nuclear features, whereas low magnification patches demonstrate distribution of tissue types and architectural growth patterns of benign and malignant processes.

There are several works using multiple magnifications to analyze images from tissue samples. A multi-input multi-output CNN is presented by analyzing an input image in multiple resolutions to segment cells in fluorescence microscopy

images [36]. Similarly, a stain-aware multi-scale CNN is further designed for instance cell segmentation in histology images [37]. To segment tumor regions in the CAMELYON dataset [24], a binary segmentation CNN is described in [38]. In this work, four encoders for different magnifications are implemented but only one decoder is used to generate the final segmentation predictions. More recently, a CNN architecture composed of three expert networks for different magnifications, a weighting network to automatically select weights to emphasize specific magnifications based on input patches, and an aggregating network to produce final segmentation predictions is developed in [39]. Here, feature maps are not shared between the three expert networks until the last layer which can limit utilizing feature maps from multiple magnifications. Architectures designed in [38] and [39] center-crop feature maps in lower magnifications and then upsample the cropped feature maps to match the size and magnification during concatenations which can also limit the usage of feature maps on cropped boundary regions in lower magnifications.

In this paper, we present a Deep Multi-Magnification Network (DMMN) to accurately segment multiple subtypes in images of breast tissue. Our DMMN architecture has multiple encoders, multiple decoders, and multiple concatenations between decoders to have richer feature maps in intermediate layers. To fully utilize feature maps in lower magnifications, we center-crops intermediate feature maps during concatenations. By concatenating intermediate feature maps in each layer, feature maps from multiple magnifications can be used to produce accurate segmentation predictions. To train our DMMN, we partially annotate WSIs, similarly done as [40], to reduce the burden of annotations. Our DMMN model trained by our partial annotations can learn not only features of each subtype, but also morphological relationship between subtypes especially transitions from one subtype to another subtype on boundary regions, which leads to outstanding segmentation performance. We test our multi-magnification model on two breast datasets and observe that our model consistently outperforms other architectures. Our method can be used to automatically segment cancer regions on breast images to assist in diagnosis of patients' status and to decide

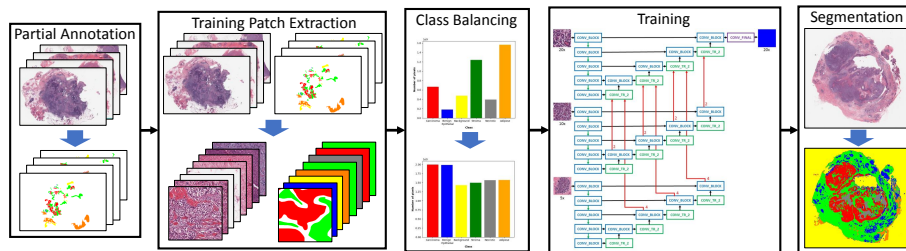


Figure 2: Block diagram of the proposed method with our Deep Multi-Magnification Network. The first step of our method is to partially annotate training whole slide images. After extracting training patches from the partial annotations and balancing the number of pixels between classes, our Deep Multi-Magnification Network is trained. The trained network is used for multi-class tissue segmentation of whole slide images.

future treatments.

## 2. Proposed Method

Figure 2 shows the block diagram of our proposed method. Our goal is to segment multiple subtypes on breast images using our Deep Multi-Magnification Network (DMMN). First of all, manual annotation is done on the training dataset with  $C$  classes. Here, this annotation is done partially for an efficient and fast process. To train our multi-class segmentation DMMN, patches are extracted from whole slide images (WSIs) and the corresponding annotations. Before training our DMMN with the extracted patches, we use elastic deformation [17, 41] to multiply patches belonging to rare classes to balance the number of annotated pixels between classes. After the training step is done, the model can be used for multi-class segmentation of breast cancer images. We have implemented our system in PyTorch [42].

### 2.1. Partial Annotation

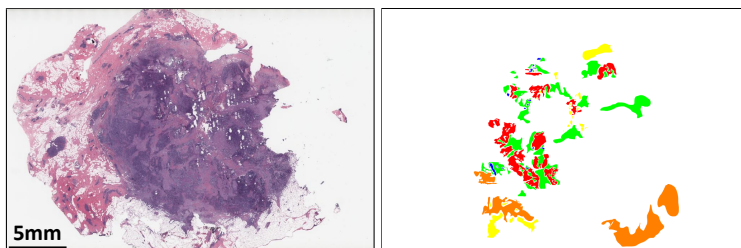
A large set of annotations is needed for supervised learning, but this is generally an expensive step requiring pathologists' time and effort. Especially, due to giga-pixel scale of image size, exhaustive annotation to label all pixels

in WSIs is not practical. Many works are done using public datasets such as CAMELYON datasets [24, 25] but public datasets are designed for specific applications and may not be generalized to others. To segment multiple tissue subtypes on our breast training dataset, we partially annotate images.

For partial annotations, we (1) annotated the entire subtype components without cropping and (2) reduced the thickness of unlabeled regions between the subtype component. An example of our proposed partial annotation is shown in Figure 3, where a partially annotated image overlaid on a whole slide image is shown in Figure 3(c). Note white regions in Figure 3(b) are unlabeled. Exhaustive annotations, especially on boundary regions, without any overlapping portions and subsequent inaccurate labeling can be challenging given the regions merge into each other seamlessly. Additionally, the time required for complete, exhaustive labeling is immense. By reducing the thickness of these unlabeled boundary regions, our CNN models trained by our partial annotation can learn the spatial relationships between subtypes such as transitions from one subtype to another subtype and generate precise segmentation boundaries. A partially annotated image in Figure 3(c) shows unlabeled regions between carcinoma in red and stroma in green are thinned. This is different from the partial annotation done in [40] where annotated regions of different subtypes were too widely spaced and thus unsuitable for training spatial relationships between them. The work in [40] also suggests exhaustive annotation in sub-regions of WSIs to reduce annotation efforts, but if the subtype components are cropped the CNN model cannot learn the growth pattern of the different subtypes. In this work, we annotated each subtype component entirely to let our CNN model learn the growth pattern of all subtypes. According to our proposed partial annotation, an experienced pathologist can spend approximately 30 minutes to annotate one WSI.

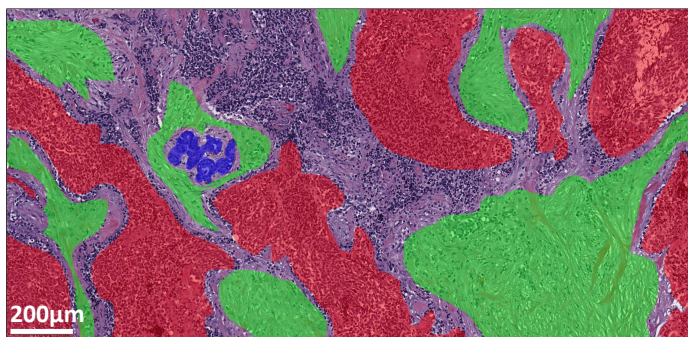
## *2.2. Training Patch Extraction*

Whole slide images are generally too large to process in slide-level using convolutional neural networks. To analyze WSIs, patch-based methods are used



(a) Whole Slide Image

(b) Partial Annotation



(c) The Partial Annotation Overlaid on the Whole Slide Image

Figure 3: An example of partial annotation. (a) A whole slide image from breast tissue. (b) A partially annotated image where multiple tissue subtypes are annotated in distinct colors and white regions are unlabeled. (c) The partial annotation overlaid on the whole slide image. Subtype components are annotated without cropping while reducing the thickness of unlabeled regions between the subtype components. Here, carcinoma is annotated in red, benign epithelial in blue, background in yellow, stroma in green, necrotic in gray, and adipose in orange.

where patches extracted from an image is processed by a CNN and then the outputs are combined for slide-level analysis. One limitation of the patch-based methods is that they only look at patches in a single magnification with a limited field-of-view.

To have a wider field-of-view, a set of multi-magnification patches is extracted to train our DMMN. In this work, we set the size of a target patch to be analyzed in a WSI be  $256 \times 256$  pixels in  $20\times$  magnification. To analyze the target patch, an input patch with size of  $1024 \times 1024$  pixels in  $20\times$  is ex-

tracted from the image where the target patch is located at the center of the input patch. From this input patch, a set of three multi-magnification patches is extracted. The first patch is extracted from the center of the input patch with size of  $256 \times 256$  pixels in  $20\times$ , which is the same location and magnification with the target patch. The second patch is extracted from the center of the input patch with size of  $512 \times 512$  pixels and downsampled by a factor of 2 to become size of  $256 \times 256$  pixels in  $10\times$ . Lastly, the third patch is generated by downsampling the input patch by a factor of 4 to become size of  $256 \times 256$  pixels in  $5\times$ . The set of three patches in different magnifications becomes the input to our DMMN to segment cancer in the target patch with size of  $256 \times 256$  pixels. Input patches are extracted from training images if more than 1% of pixels in the corresponding target patches are annotated. The stride to  $x$  and  $y$ -directions is 256 pixels to avoid overlapping target patches. Note target patches may have multiple class labels.

### 2.3. Class Balancing

Class balancing is a prerequisite step for training CNNs for accurate performance [43]. When the number of training patches in one class dominates the number of training patches in another class, CNNs cannot properly learn features from the minor class. In this work, class imbalance is observed in our annotations. For example, the number of annotated pixels in carcinoma regions dominates the number of annotated pixels in benign epithelial regions. To balance between classes, elastic deformation [17, 41] is used to multiply training patches belonging to minor classes.

Elastic deformation is widely used as a data augmentation technique in biomedical images due to the squiggling shape of biological structures. To perform elastic deformation on a patch, a set of grid points in the patch is selected and displaced randomly by a normal distribution with a standard deviation of  $\sigma$ . According to the displacements of the grid points, all pixels in the patch are displaced by bicubic interpolation. In this work, we empirically set the grid points by  $17 \times 17$  and  $\sigma = 4$  to avoid excessive distortions of nuclei to lose their

features.

The number of patches to be multiplied needs to be carefully selected to balance the number of pixels between classes. Here, we define a rate of elastic deformation for a class  $c$ , denoted as  $r_c$ , to be the number of patches to be multiplied for the class  $c$  and a class order to decide the order of classes when multiplying patches. The rate can be selected based on the number of pixels in each class. The rate is a non-negative integer and elastic deformation is not performed if the rate is 0. The class order can be decided based on applications. For example, if one desires an accurate segmentation on carcinoma regions, then a class of carcinoma would have a higher order than other classes. To multiply patches, each patch needs to be classified to a class  $c$  if the patch contains a pixel label classified to  $c$ . If a patch contains pixels in multiple classes, a class with a higher class order becomes the class of the patch. After patches are classified,  $r_c$  number of patches will be multiplied for each patch in class  $c$  using elastic deformation. Once class balancing is done, all patches are used to train CNNs.

#### 2.4. CNN Architectures

Figure 4 shows architectures of a Deep Single-Magnification Network (DSMN) and Deep Multi-Magnification Networks (DMMNs) for multi-class tissue segmentation. The size of input patches is  $256 \times 256$  pixels and the size of an output prediction is  $256 \times 256$  pixels. CONV\_BLOCK contains two sets of a convolutional layer with kernel size of  $3 \times 3$  with padding of 1 followed by a rectified linear unit (ReLU) activation function in series. CONV\_TR\_ $u$  contains a transposed convolutional layer followed by the ReLU activation function where  $u$  is an upsampling rate. Note CONV\_TR\_4 is composed of two CONV\_TR\_2 in series. CONV\_FINAL contains a convolutional layer with kernel size of  $3 \times 3$  with padding of 1, the ReLU activation function, and a convolutional layer with kernel size of  $1 \times 1$  to output  $C$  channels. The final segmentation predictions are produced using the softmax operation. Green arrows are max-pooling operations by a factor of 2 and red arrows are center-crop operations where cropping rates are written in red. The center-crop operations crop the center regions of

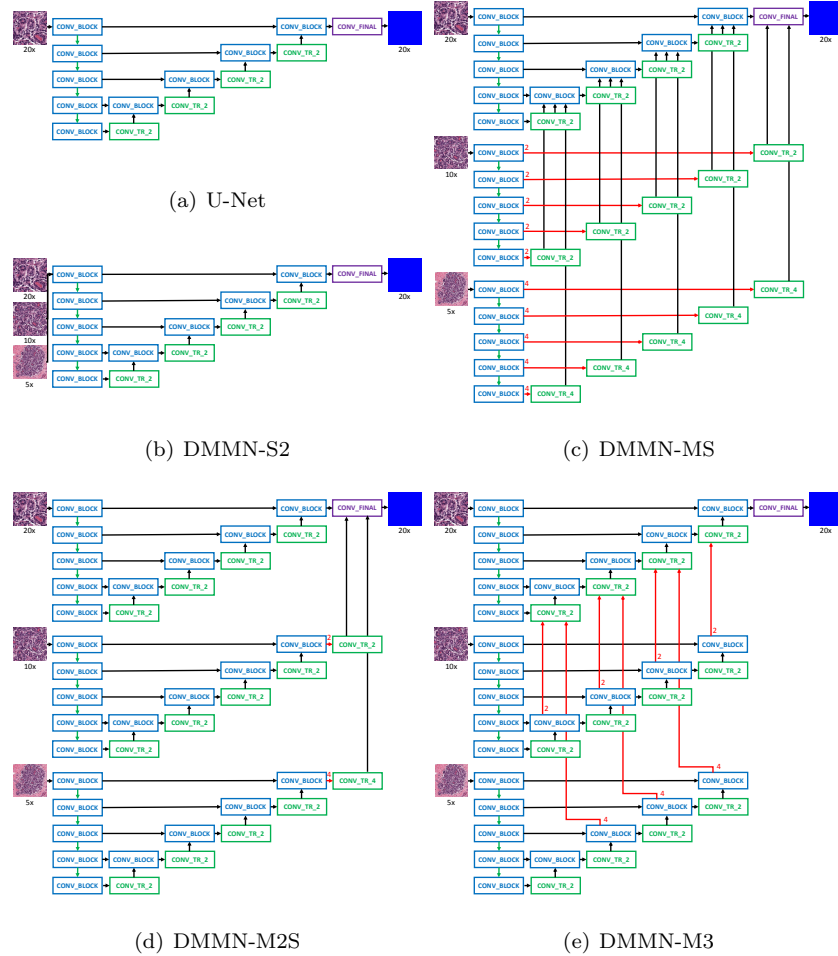


Figure 4: CNN architectures for multi-class tissue segmentation of a Deep Single-Magnification Network (DSMN) in (a) utilizing a patch from a single magnification and Deep Multi-Magnification Networks (DMMNs) in (b-e) utilizing multiple patches in various magnifications. (a) U-Net [17] is used as our DSMN architecture. (b) Single-Encoder Single-Decoder (DMMN-S2) is a DMMN architecture where multiple patches are concatenated and used as an input to the U-Net architecture. (c) Multi-Encoder Single-Decoder (DMMN-MS) is a DMMN architecture having only one decoder. (d) Multi-Encoder Multi-Decoder Single-Concatenation (DMMN-M2S) is a DMMN architecture where feature maps from multiple magnifications are only concatenated at the final layer. (e) Our proposed Multi-Encoder Multi-Decoder Multi-Concatenation (DMMN-M3) is a DMMN architecture where feature maps are concatenated during intermediate layers to enrich feature maps in the decoder of the highest magnification.



feature maps in all channels by the cropping rate to fit the size and magnification of feature maps for the next operation. During the center-crop operations, the width and height of the cropped feature maps become a half and a quarter of the width and height of the input feature maps if the cropping rate is 2 and 4, respectively.

An original U-Net [17] architecture in Figure 4(a) uses a single magnification patch in  $20\times$  to produce the corresponding segmentation predictions. A Single-Encoder Single-Decoder (DMMN-S2) architecture in Figure 4(b) uses multiple patches in  $20\times$ ,  $10\times$ , and  $5\times$  magnifications, but they are concatenated and used as an input to the U-Net architecture [17]. A Multi-Encoder Single-Decoder (DMMN-MS) architecture in Figure 4(c), motivated by the work in [38], uses multiple encoders in  $20\times$ ,  $10\times$ , and  $5\times$  magnifications, but only uses a single decoder in  $20\times$  by transferring feature maps from encoders in  $10\times$  and  $5\times$ . A Multi-Encoder Multi-Decoder Single-Concatenation (DMMN-M2S) architecture in Figure 4(d), motivated by the work in [39], has multiple encoders and the corresponding decoders in  $20\times$ ,  $10\times$ , and  $5\times$  magnifications, but the concatenation is done only at the end of the encoder-decoder pairs. Here, the weighting CNN in [39] is excluded for a fair comparison with other architectures. Lastly, our proposed Multi-Encoder Multi-Decoder Multi-Concatenation (DMMN-M3) architecture in Figure 4(e) has multiple encoders and decoders and has concatenations between the decoders in multiple layers to enrich feature maps from the decoders in  $10\times$  and  $5\times$  to the decoder in  $20\times$ . Additionally, we use center-crop operations while transferring feature maps from the decoders in  $10\times$  and  $5\times$  to the decoder in  $20\times$  to extract features in  $10\times$  and  $5\times$  as much as possible. Note DMMN-MS and DMMN-M2S use center-crop operations in  $10\times$  and  $5\times$  levels where cropped regions before concatenation can limit feature extraction processes in lower magnifications.

### 2.5. CNN Training

The balanced set of patches from Section 2.3 is used to train our multi-class segmentation CNNs. We used a weighted cross entropy as our training loss

function with  $N$  pixels in a patch and  $C$  classes:

$$L(t^{gt}, t^{pred}) = -\frac{1}{N} \sum_{p=1}^N \sum_{c=1}^C w_c t_c^{gt}(p) \log t_c^{pred}(p) \quad (1)$$

where  $t_c^{gt}$  and  $t_c^{pred}$  are two-dimensional ground truth and segmentation predictions for a class  $c$ , respectively.  $t_c^{gt}(p)$  is a binary ground truth value for a class  $c$  at a pixel location  $p$ , either 0 or 1, and  $t_c^{pred}(p)$  is a segmentation prediction value for a class  $c$  at a pixel location  $p$ , between 0 and 1. In Equation 1, a weight for class  $c$ ,  $w_c$  is defined as

$$w_c = 1 - \frac{N_c}{\sum_c N_c} \quad (2)$$

where  $N_c$  is the number of pixels for class  $c$  in a training set. Unlabeled pixels do not contribute to the training loss function. We use stochastic gradient descent (SGD) with a learning rate of  $5 \times 10^{-5}$ , a momentum of 0.99, and a weight decay of  $10^{-4}$  for 20 epochs for optimization. A CNN model with the highest mean intersection-over-union (mIOU) on validation images is selected as the final model. During training, data augmentation using random rotation, vertical and horizontal flip, brightness, contrast, and color jittering is used.

## 2.6. Multi-Class Segmentation

Multi-class tissue segmentation on breast images can be done using the trained CNN. The final label in each pixel is selected as a class which has the largest prediction value among the  $C$  classes. An input patch with size of  $1024 \times 1024$  pixels is extracted from a WSI to generate a set of three patches with size of  $256 \times 256$  pixels in  $20\times$ ,  $10\times$ , and  $5\times$  magnifications by the process described in Section 2.2. The set of three patches is processed by our trained CNN. The segmentation predictions with size of  $256 \times 256$  pixels are located at the center location of the input patch. Input patches are extracted from the top-left corner of the WSI with a stride of 256 pixels in  $x$  and  $y$  directions to process the entire WSI. Zero-padding is done to extract input patches on the boundary of WSIs. The Otsu thresholding technique [32] can be used before

extracting patches as optional to remove background regions to speed up the segmentation process. No pre-processing step is used during segmentation.

### 3. Experimental Results

Two breast datasets, Dataset-I and Dataset-II, were used to train and evaluate various multi-class tissue segmentation methods. Dataset-I is composed of whole slide images (WSIs) with Triple-Negative Breast Cancer (TNBC) containing high grade invasive ductal carcinoma (IDC). Dataset-II is composed of WSIs from lumpectomy and breast margins containing IDC and ductal carcinoma in situ (DCIS) of various histologic grades. All WSIs in Dataset-I and Dataset-II were from different patients, were hematoxylin and eosin (H&E) stained, and were digitized at Memorial Sloan Kettering Cancer Center. Dataset-I was digitized by Aperio XT where microns per pixel (MPP) in  $20\times$  is 0.4979 and Dataset-II was digitized by Aperio AT2 where MPP in  $20\times$  is 0.5021. WSIs in Dataset-I were partially annotated by two pathologists and WSIs in Dataset-II were partially annotated by another pathologist.

Thirty two WSIs from Dataset-I were used to train and validate segmentation models. The number of whole slide images and the number of patches before and after class balancing to train and validate the models are shown in Table 1. No images from Dataset-II were used during training. In our work, only 5.34% of pixels of training WSIs were annotated. Our models can predict 6 classes ( $C = 6$ ) which are carcinoma, benign epithelial, background, stroma, necrotic, and adipose. Note that background is defined as regions which are not tissue. To balance the number of annotated pixels between classes, we empirically set  $r_2 = 10$ ,  $r_1 = 2$ ,  $r_5 = 3$ ,  $r_3 = 1$ ,  $r_4 = 0$ , and  $r_6 = 0$  where  $r_1$ ,  $r_2$ ,  $r_3$ ,  $r_4$ ,  $r_5$ , and  $r_6$  are rates of elastic deformation of carcinoma, benign epithelial, background, stroma, necrotic, and adipose, respectively. Benign epithelial was selected as the highest class order followed by carcinoma, necrotic, and background, because we want to accurately segment carcinoma regions and separate benign epithelial to reduce false segmen-

tation. Figure 5 shows the number of annotated pixels between classes are balanced using elastic deformation. We trained two Deep Single-Magnification Networks (DSMNs), SegNet [16] architecture and U-Net [17] architecture, and four Deep Multi-Magnification Networks (DMMNs), Single-Encoder Single-Decoder (DMMN-S2) architecture, Multi-Encoder Single-Decoder (DMMN-MS) architecture, Multi-Encoder Multi-Decoder Single-Concatenation (DMMN-M2S) architecture, and our proposed Multi-Encoder Multi-Decoder Multi-Concatenation (DMMN-M3) architecture. The number of convolutional layers, the number of downsampling and upsampling layers, and the number of channels are kept the same between the SegNet architecture used in this experiment and the original U-Net architecture. Also, the number of channels on DMMN-MS, DMMN-M2S, and DMMN-M3 are reduced by a factor of 2 from an original U-Net architecture. Table 2 lists the models we compared, the number of trainable parameters, and segmentation time, where the segmentation time was measured on a whole slide image in Figure 7 whose size is  $53,711 \times 38,380$  pixels with 31,500 patches using a single NVIDIA GeForce GTX TITAN X GPU.

Table 1: The number of whole slide images and the number of patches before and after class balancing from Dataset-I used to train and validate segmentation models

	Training	Validation
Whole slide images	26	6
Patches before class balancing	52,769	9,506
Patches after class balancing	115,844	24,119

We processed 55 testing images from Dataset-I and 34 testing images from Dataset-II to evaluate various models. Figure 6 depicts multi-class segmentation predictions in a WSI from Dataset-I by SegNet [16] architecture, U-Net [17] architecture, DMMN-S2 architecture, DMMN-MS architecture, DMMN-M2S architecture, and our proposed DMMN-M3 architecture, and Figure 7 depicts multi-class segmentation predictions in a patch containing invasive ductal carcinoma (IDC) with size of  $1024 \times 1024$  pixels in  $10\times$  magnification from the WSI

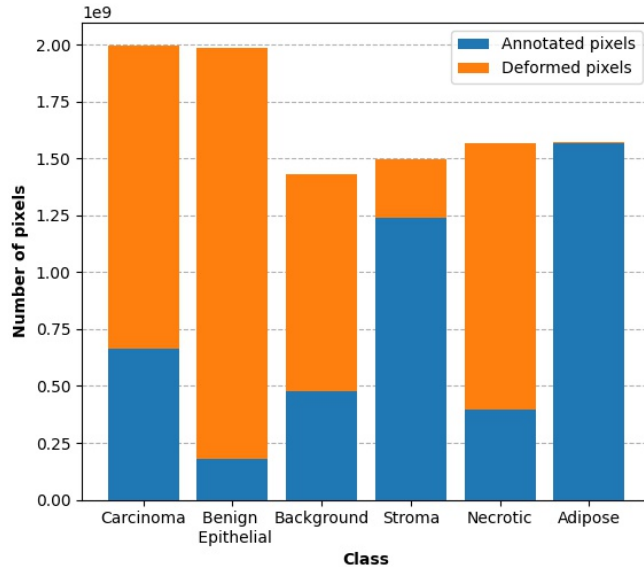


Figure 5: Class balancing using elastic deformation in the training breast dataset.

in Figure 6. Similarly, Figure 8 depicts multi-class segmentation predictions in a WSI from Dataset-I, Figure 9 depicts multi-class segmentation predictions in a patch containing benign epithelial from the WSI in Figure 8, Figure 10 depicts multi-class segmentation predictions in a WSI from Dataset-II, and Figure 11 depicts multi-class segmentation predictions in a patch containing ductal carcinoma in situ (DCIS) from the WSI in Figure 10. Tissue subtypes are labeled in distinct colors such as carcinoma in red, benign epithelial in blue, background in yellow, stroma in green, necrotic in gray, and adipose in orange. White regions in Figures 6(b), 7(b), 8(b), 9(b), 10(b), and 11(b) are unlabeled. The Otsu thresholding technique [32] was used to extract patches only on foreground regions of the WSIs from Dataset-II digitized from a different scanner because we observed that models are sensitive to background noise leading mis-segmentation on background regions. White regions in Figure 10(c-h) are removed by the Otsu technique [32].

We evaluated our predictions numerically using intersection-over-union (IOU),

Table 2: The number of trainable parameters and computational time for multi-class segmentation models

Model	Trainable Parameters	Segmentation Time
SegNet [16]	18,881,543	7 min 48 sec
U-Net [17]	34,550,663	12 min 50 sec
DMMN-S2	34,554,119	13 min 16 sec
DMMN-MS	30,647,207	13 min 6 sec
DMMN-M2S	25,947,047	16 min 21 sec
DMMN-M3	27,071,303	14 min 52 sec

recall, and precision which are defined as:

$$IOU = \frac{N_{TP}}{N_{TP} + N_{FP} + N_{FN}} \quad (3)$$

$$Recall = \frac{N_{TP}}{N_{TP} + N_{FN}} \quad (4)$$

$$Precision = \frac{N_{TP}}{N_{TP} + N_{FP}} \quad (5)$$

where  $N_{TP}$ ,  $N_{FP}$ , and  $N_{FN}$  are the number of pixels for true-positive, false-positive, and false-negative, respectively. Tables 3 and 4 shows mean IOU (mIOU), mean recall (mRecall), and mean precision (mPrecision) on Dataset-I and Dataset-II, respectively, where mIOU is used as our main evaluation metric to select the best performing model. Figures 12 and 13 show confusion matrices from the models on Dataset-I and Dataset-II, respectively. Note that necrotic, adipose, and background were excluded for evaluating Dataset-II because (1) Dataset-II does not contain large necrotic regions and (2) most of adipose and background regions were not segmented due to the Otsu technique [32].

Based on our visual and numerical evaluations on Dataset-I, both DSMNs had blocky boundaries between subtypes, shown in Figures 7(c,d) and 9(c,d) due to their narrow field-of-view. DMMN-S2 also had blocky boundaries between subtypes, shown in Figures 7(e) and 9(e), because patches from multiple

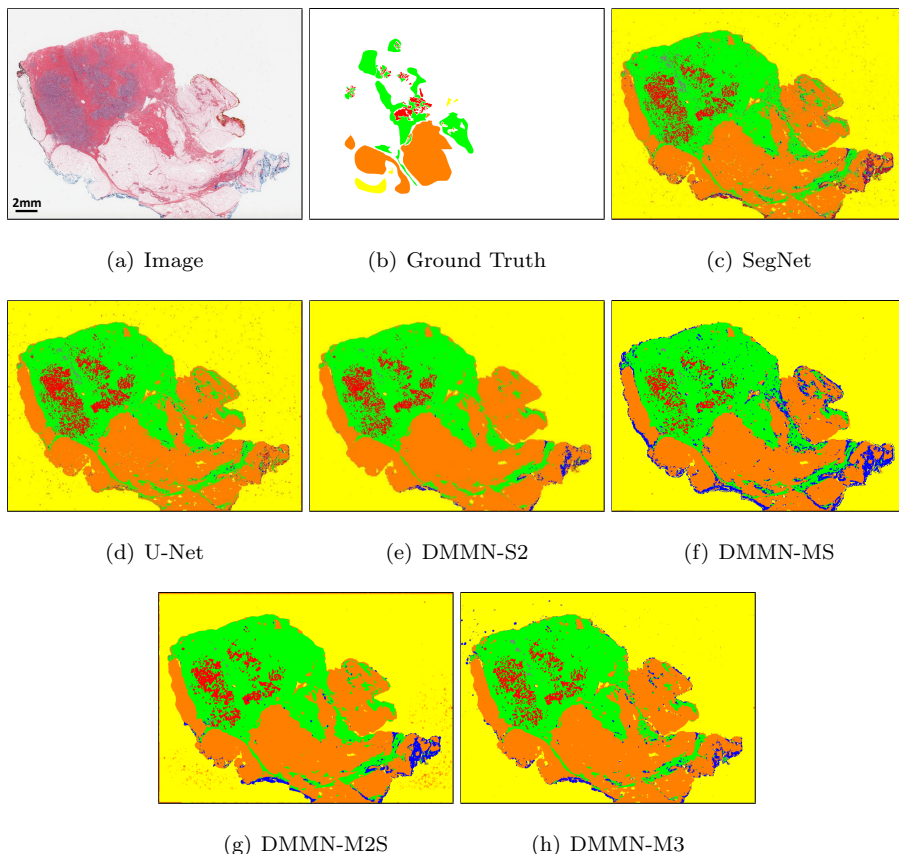


Figure 6: Multi-class tissue segmentation predictions of a whole slide image from Dataset-I using two Deep Single-Magnification Networks (DSMN), SegNet [16] and U-Net [17], and four Deep Multi-Magnification Networks (DMMNs), Single-Encoder Single-Decoder (DMMN-S2), Multi-Encoder Single-Decoder (DMMN-MS), Multi-Encoder Multi-Decoder Single-Concatenation (DMMN-M2S), and our proposed Multi-Encoder Multi-Decoder Multi-Concatenation (DMMN-M3).

magnifications are concatenated early in the model so various features from multiple magnifications could not be fully extracted. These blockly predictions led to low mIOU, low mRecall, and low mPrecision in Table 3. DMMN-MS and DMMN-M2S had smoother boundaries between subtypes, but they did not have consistent predictions throughout subtypes. For example, DMMN-MS and DMMN-M2S cannot predict necrotic successfully according to Figure




Figure 7: Multi-class tissue segmentation predictions of invasive ductal carcinoma (IDC) in red from Dataset-I using two Deep Single-Magnification Networks (DSMNs), SegNet [16] and U-Net [17], and four Deep Multi-Magnification Networks (DMMNs), Single-Encoder Single-Decoder (DMMN-S2), Multi-Encoder Single-Decoder (DMMN-MS), Multi-Encoder Multi-Decoder Single-Concatenation (DMMN-M2S), and our proposed Multi-Encoder Multi-Decoder Multi-Concatenation (DMMN-M3).



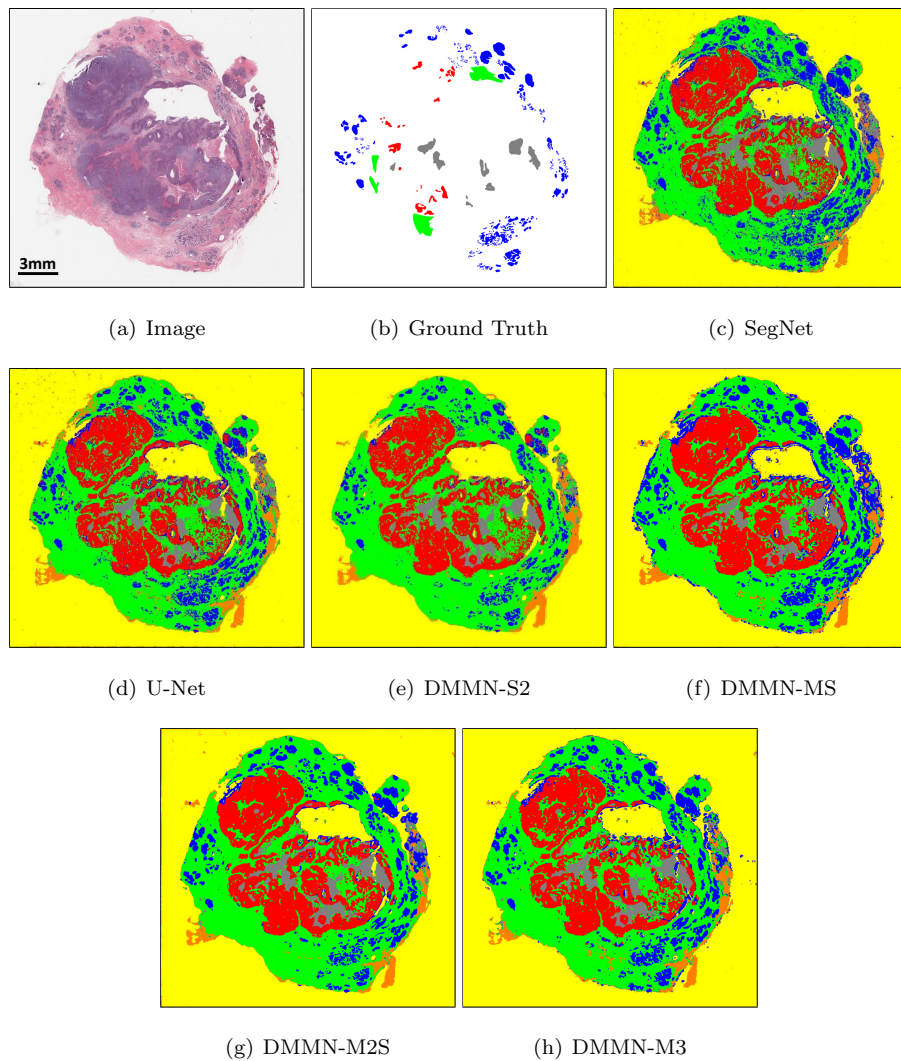


Figure 8: Multi-class tissue segmentation predictions of a whole slide image from Dataset-I using two Deep Single-Magnification Networks (DSMNs), SegNet [16] and U-Net [17], and four Deep Multi-Magnification Networks (DMMNs), Single-Encoder Single-Decoder (DMMN-S2), Multi-Encoder Single-Decoder (DMMN-MS), Multi-Encoder Multi-Decoder Single-Concatenation (DMMN-M2S), and our proposed Multi-Encoder Multi-Decoder Multi-Concatenation (DMMN-M3).

12(d,e). Our proposed DMMN-M3 has shown accurate predictions throughout all subtypes, shown in Figure 12(f), leading to the best mIOU, mRecall, and

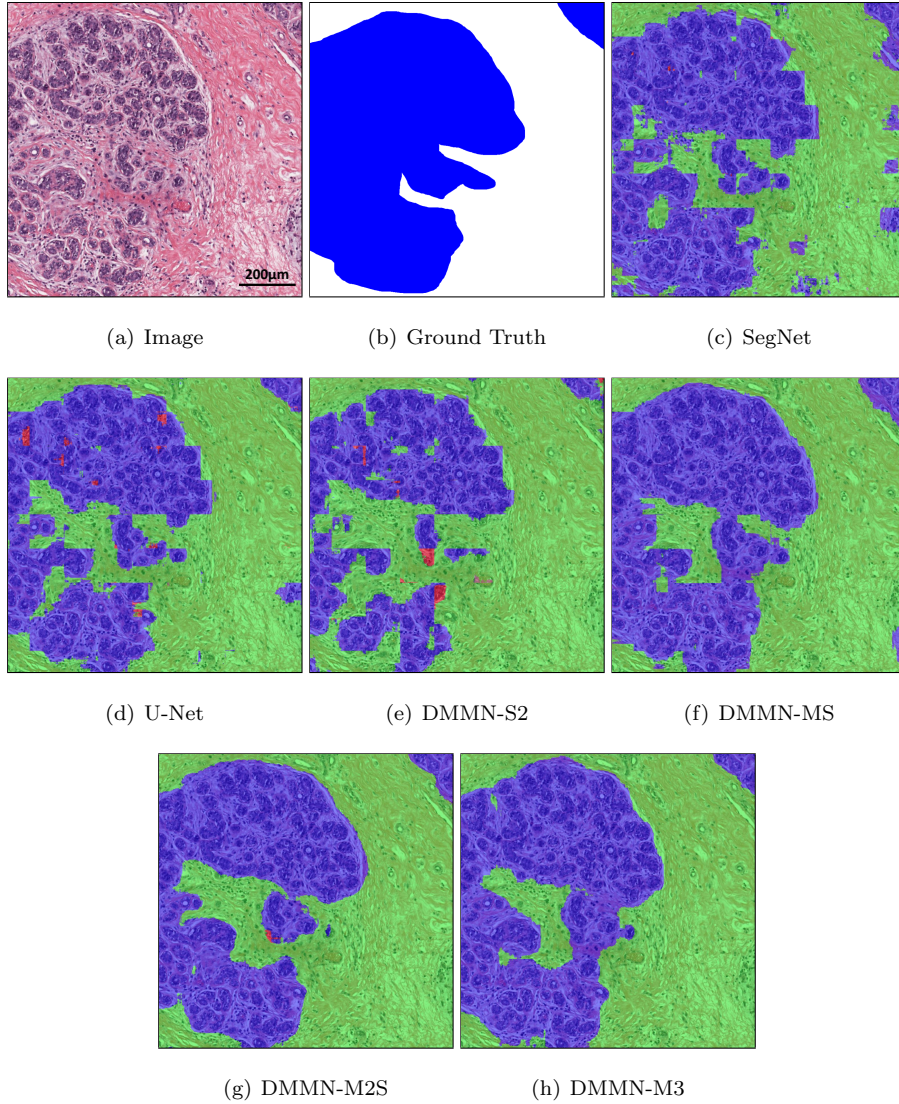


Figure 9: Multi-class tissue segmentation predictions of benign epithelial in blue from Dataset-I using two Deep Single-Magnification Networks (DSMNs), SegNet [16] and U-Net [17], and four Deep Multi-Magnification Networks (DMMNs), Single-Encoder Single-Decoder (DMMN-S2), Multi-Encoder Single-Decoder (DMMN-MS), Multi-Encoder Multi-Decoder Single-Concatenation (DMMN-M2S), and our proposed Multi-Encoder Multi-Decoder Multi-Concatenation (DMMN-M3).




Figure 10: Multi-class tissue segmentation predictions of a whole slide image from Dataset-II using two Deep Single-Magnification Networks (DSMNs), SegNet [16] and U-Net [17], and four Deep Multi-Magnification Networks (DMMNs), Single-Encoder Single-Decoder (DMMN-S2), Multi-Encoder Single-Decoder (DMMN-MS), Multi-Encoder Multi-Decoder Single-Concatenation (DMMN-M2S), and our proposed Multi-Encoder Multi-Decoder Multi-Concatenation (DMMN-M3).

mPrecision in Table 3.

Our models were trained on Dataset-I and we kept aside images in Dataset-II, annotated by a different pathologist, for our testing set. We still observed blocky boundaries on predictions done by SegNet, U-Net, and DMMN-S2 on Dataset-II, shown in Figure 11(c,d,e). We noticed predictions by DMMN-M2S were not successful where large regions are falsely segmented as benign epithelial in Figures 10(g) and 11(g). Figure 11(h) demonstrates that our proposed DMMN-M3 segments subtypes with smoother and clearer boundaries.






Figure 11: Multi-class tissue segmentation predictions of ductal carcinoma in situ (DCIS) in red from Dataset-II using two Deep Single-Magnification Networks (DSMNs), SegNet [16] and U-Net [17], and four Deep Multi-Magnification Networks (DMMNs), Single-Encoder Single-Decoder (DMMN-S2), Multi-Encoder Single-Decoder (DMMN-MS), Multi-Encoder Multi-Decoder Single-Concatenation (DMMN-M2S), and our proposed Multi-Encoder Multi-Decoder Multi-Concatenation (DMMN-M3).

Table 3: Mean IOU, Recall, and Precision on Dataset-I

Model	mIOU	mRecall	mPrecision
SegNet [16]	0.766	0.887	0.850
U-Net [17]	0.803	0.896	0.879
DMMN-S2	0.833	0.900	0.910
DMMN-MS	0.836	0.918	0.906
DMMN-M2S	0.848	0.931	0.904
DMMN-M3	<b>0.870</b>	<b>0.939</b>	<b>0.922</b>

Table 4: Mean IOU, Recall, and Precision on Dataset-II

Model	mIOU	mRecall	mPrecision
SegNet [16]	0.682	0.872	0.784
U-Net [17]	<b>0.726</b>	0.882	<b>0.819</b>
DMMN-S2	0.639	0.855	0.764
DMMN-MS	0.720	0.897	0.806
DMMN-M2S	0.693	0.877	0.801
DMMN-M3	0.706	<b>0.898</b>	0.795

According to Figure 13(f), DMMN-M3 segmented many carcinoma pixels as benign epithelial on Dataset-II causing low mIOU in Table 4. We observed that well-differentiated carcinomas were segmented as benign epithelial by DMMN-M3, shown in Figure 14. Well-differentiated carcinomas, known to be morphologically similar to benign cells, were not presented in Dataset-I composed of high grade Triple-Negative Breast Cancer (TNBC). DMMN-M3 trained by Dataset-I alone would not be able to learn morphological features of well-differentiated carcinomas, causing inaccurate segmentation on them in Dataset-II. We numerically evaluated the 6 models on 29 WSIs in Dataset-II by excluding 5 images with well-differentiated carcinomas, and Table 5 shows DMMN-M3 outperforms other methods for higher histologic grades based on mIOU, mRecall, and mPrecision. Although our current DMMN-M3 model may

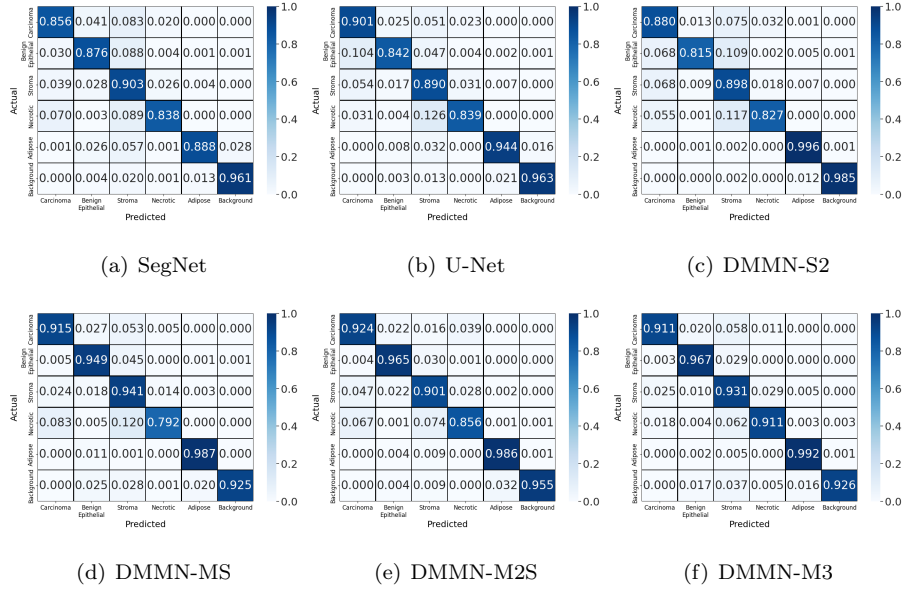


Figure 12: Confusion matrices evaluating carcinoma, benign epithelial, stroma, necrotic, adipose, and background segmentation on Dataset-I based on two Deep Single-Magnification Networks (DSMN), SegNet [16] and U-Net [17], and four Deep Multi-Magnification Networks (DMMNs), Single-Encoder Single-Decoder (DMMN-S2), Multi-Encoder Single-Decoder (DMMN-MS), Multi-Encoder Multi-Decoder Single-Concatenation (DMMN-M2S), and our proposed Multi-Encoder Multi-Decoder Multi-Concatenation (DMMN-M3).

be challenged to segment well-differentiated carcinomas due to their absence in the training set, our proposed model, with additional training annotations of well-differentiated carcinomas, can be used to successfully segment breast whole slide images to assist pathologists for breast cancer assessments.

#### 4. Conclusion

We described a Deep Multi-Magnification Network (DMMN) for an accurate multi-class tissue segmentation of whole slide images. Our model is trained by partially-annotated images to reduce time and effort for annotators. Although the annotation was partially done, our model was able to learn not only spatial characteristics within a class but also spatial relationship between classes. Our

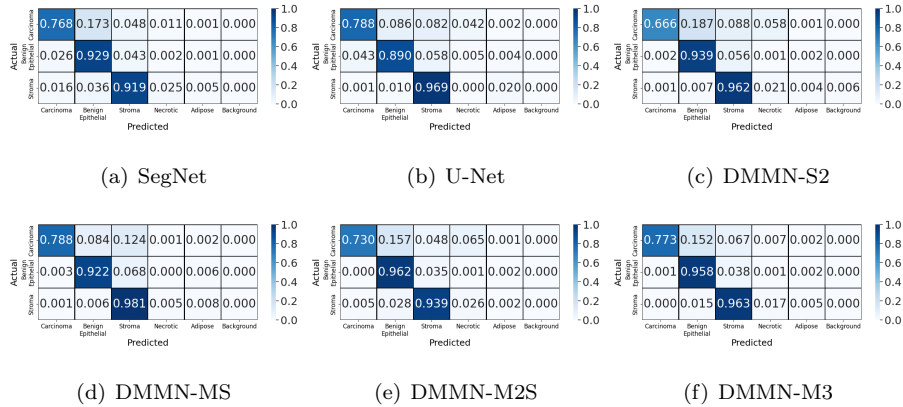


Figure 13: Confusion matrices evaluating carcinoma, benign epithelial, and stroma segmentation on Dataset-II based on two Deep Single-Magnification Networks (DSMNs), SegNet [16] and U-Net [17], and four Deep Multi-Magnification Networks (DMMNs), Single-Encoder Single-Decoder (DMMN-S2), Multi-Encoder Single-Decoder (DMMN-MS), Multi-Encoder Multi-Decoder Single-Concatenation (DMMN-M2S), and our proposed Multi-Encoder Multi-Decoder Multi-Concatenation (DMMN-M3). Necrotic, adipose, and background are excluded from the confusion matrices on Dataset-II due to the lack of pixels being evaluated.

DMMN architecture looks at all  $20\times$ ,  $10\times$ , and  $5\times$  magnifications to have a wider field-of-view to make more accurate predictions based on feature maps from multiple magnifications. We were able to improve previous DMMNs by transferring intermediate feature maps from decoders in  $10\times$  and  $5\times$  to a decoder in  $20\times$  to enrich feature maps. Our implementation achieved outstanding segmentation performance on breast datasets that can be used to decide patients' future treatment. One main challenge we encountered is that our model may not successfully segment well-differentiated carcinomas presented in breast images because well-differentiated carcinomas were not included in training annotation. We also observed that our model can be sensitive to background noises potentially leading to mis-segmentation on background regions if whole slide images are digitized by other scanners. In the future, we plan to develop a more accurate DMMN model where various cancer structures and background noise patterns are included during training.

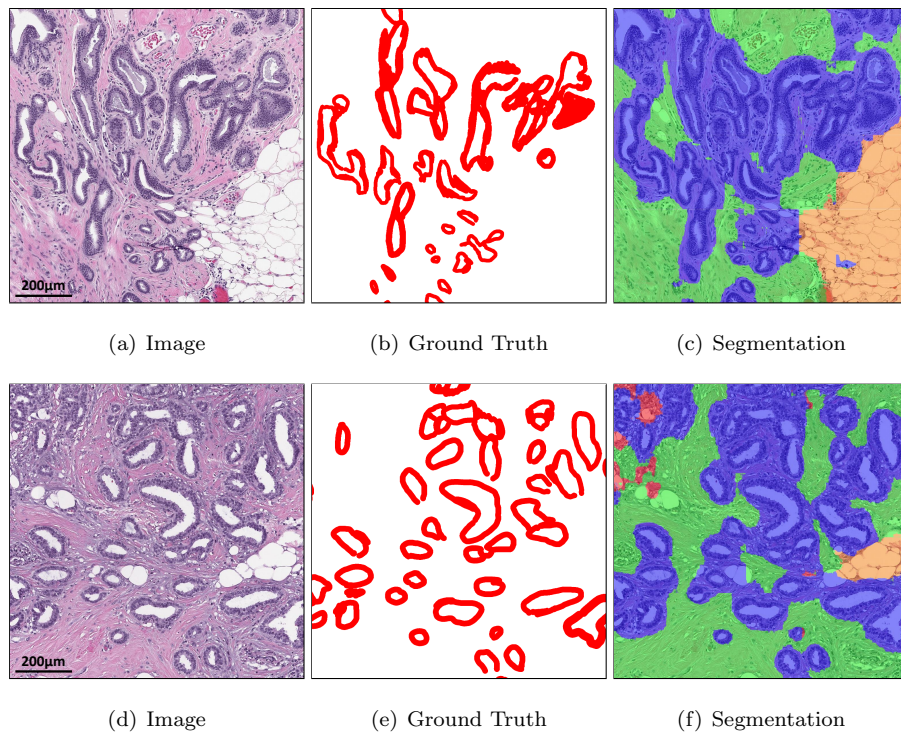


Figure 14: Multi-class tissue segmentation predictions of well-differentiated carcinomas in red from Dataset-II using our proposed Multi-Encoder Multi-Decoder Multi-Concatenation (DMMN-M3).

## 5. Acknowledgments

This work was supported by the Warren Alpert Foundation Center for Digital and Computational Pathology at Memorial Sloan Kettering Cancer Center and the NIH/NCI Cancer Center Support Grant P30 CA008748.

## 6. Conflict of interest

T.J.F. is the Chief Scientific Officer, co-founders and equity holders of Paige.AI. M.G.H. is a consultant for Paige.AI and on the medical advisory board of Path-Presenter. D.J.H. and T.J.F. have intellectual property interests relevant to the work that is the subject of this paper. MSK has financial interests in Paige.AI.



Table 5: Mean IOU, Recall, and Precision on a subset of Dataset-II excluding whole slide images with well-differentiated carcinomas

Model	mIOU	mRecall	mPrecision
SegNet [16]	0.717	0.887	0.806
U-Net [17]	0.757	0.892	0.845
DMMN-S2	0.670	0.870	0.780
DMMN-MS	0.759	0.910	0.836
DMMN-M2S	0.758	0.901	0.846
DMMN-M3	<b>0.782</b>	<b>0.923</b>	<b>0.847</b>

and intellectual property interests relevant to the work that is the subject of this paper.

## References

- [1] F. Bray, J. Ferlay, I. Soerjomataram, R. L. Siegel, L. A. Torre, A. Jemal, Global cancer statistics 2018: GLOBOCAN estimates of incidence and mortality worldwide for 36 cancers in 185 countries, *CA: A Cancer Journal for Clinicians* 68 (6) (2018) 394–424.
- [2] C. E. DeSantis, J. Ma, M. M. Gaudet, L. A. Newman, K. D. Miller, A. G. Sauer, A. Jemal, R. L. Siegel, Breast cancer statistics, 2019, *CA: A Cancer Journal for Clinicians* 69 (6) (2019) 438–451.
- [3] T.-A. Moo, L. Choi, C. Culpepper, C. Olcese, A. Heerdt, L. Scalfani, T. A. King, A. S. Reiner, S. Patil, E. Brogi, M. Morrow, K. J. V. Zee, Impact of margin assessment method on positive margin rate and total volume excised, *Annals of Surgical Oncology* 21 (1) (2014) 86–92.
- [4] I. Gage, S. J. Schnitt, A. J. Nixon, B. Silver, A. Recht, S. L. Troyan, T. Eberlein, S. M. Love, R. Gelman, J. R. Harris, J. L. Connolly, Pathologic margin involvement and the risk of recurrence in patients treated with breast-conserving therapy, *Cancer* 78 (9) (1996) 1921–1928.

- [5] T. J. Fuchs, J. M. Buhmann, Computational pathology: Challenges and promises for tissue analysis, *Computerized Medical Imaging and Graphics* 35 (7) (2011) 515–530.
- [6] M. N. Gurcan, L. E. Boucheron, A. Can, A. Madabhushi, N. M. Rajpoot, B. Yener, Histopathological image analysis: A review, *IEEE Reviews in Biomedical Engineering* 2 (2009) 147–171.
- [7] M. Veta, J. P. W. Pluim, P. J. van Diest, M. A. Viergever, Breast cancer histopathology image analysis: A review, *IEEE Transactions on Biomedical Engineering* 61 (5) (2014) 1400–1411.
- [8] S. Petushi, F. U. Garcia, M. M. Haber, C. Katsinis, A. Tozeren, Large-scale computations on histology images reveal grade-differentiating parameters for breast cancer, *BMC Medical Imaging* 6 (14).
- [9] S. Naik, S. Doyle, S. Agner, A. Madabhushi, M. Feldman, J. Tomaszewski, Automated gland and nuclei segmentation for grading of prostate and breast cancer histopathology, *Proceedings of the IEEE International Symposium on Biomedical Imaging* (2008) 284–287.
- [10] S. Ali, A. Madabhushi, An integrated region-, boundary-, shape-based active contour for multiple object overlap resolution in histological imagery, *IEEE Transactions on Medical Imaging* 31 (7) (2012) 1448–1460.
- [11] K. Nguyen, A. Sarkar, A. K. Jain, Structure and context in prostatic gland segmentation and classification, *Proceedings of the Medical Image Computing and Computer-Assisted Intervention* (2012) 115–123.
- [12] Y. LeCun, Y. Bengio, G. Hinton, Deep learning, *Nature* 521 (2015) 436–444.
- [13] A. Krizhevsky, I. Sutskever, G. E. Hinton, ImageNet classification with deep convolutional neural networks, *Proceedings of the Neural Information Processing Systems* (2012) 1097–1105.

- [14] R. Girshick, J. Donahue, T. Darrell, J. Malik, Rich feature hierarchies for accurate object detection and semantic segmentation, Proceedings of the IEEE Conference on Computer Vision and Pattern Recognition (2014) 580–587.
- [15] J. Long, E. Shelhamer, T. Darrell, Fully convolutional networks for semantic segmentation, Proceedings of the IEEE Conference on Computer Vision and Pattern Recognition (2015) 3431–3440.
- [16] V. Badrinarayanan, A. Kendall, R. Cipolla, SegNet: A deep convolutional encoder-decoder architecture for image segmentation, IEEE Transactions on Pattern Analysis and Machine Intelligence 39 (12) (2017) 2481–2495.
- [17] O. Ronneberger, P. Fischer, T. Brox, U-Net: Convolutional networks for biomedical image segmentation, Proceedings of the Medical Image Computing and Computer-Assisted Intervention (2015) 231–241.
- [18] A. Janowczyk, A. Madabhushi, Deep learning for digital pathology image analysis: A comprehensive tutorial with selected use cases, Journal of Pathology Informatics 7 (29).
- [19] G. Litjens, T. Kooi, B. E. Bejnordi, A. A. A. Setio, F. Ciompi, M. Ghafoorian, J. A. W. M. van der Laak, B. van Ginneken, C. I. Sanchez, A survey on deep learning in medical image analysis, Medical Image Analysis 42 (2017) 60–88.
- [20] S. Robertson, H. Azizpour, K. Smith, J. Hartman, Digital image analysis in breast pathology—from image processing techniques to artificial intelligence, Translational Research 194 (2018) 19–35.
- [21] A. Cruz-Roa, H. Gilmore, A. Basavanthally, M. Feldman, S. Ganesan, N. N. C. Shih, J. Tomaszewski, F. A. Gonzalez, A. Madabhushi, Accurate and reproducible invasive breast cancer detection in whole-slide images: A deep learning approach for quantifying tumor extent, Scientific Reports 7 (2017) 46450:1–14.

- [22] B. E. Bejnordi, M. Mullooly, R. M. Pfeiffer, S. Fan, P. M. Vacek, D. L. Weaver, S. Herschorn, L. A. Brinton, B. van Ginneken, N. Karssemeijer, A. H. Beck, G. L. Gierach, J. A. W. M. van der Laak, M. E. Sherman, Using deep convolutional neural networks to identify and classify tumor-associated stroma in diagnostic breast biopsies, *Modern Pathology* 31 (2018) 1502–1512.
- [23] G. Campanella, M. G. Hanna, L. Geneslaw, A. Miralflor, V. W. K. Silva, K. J. Busam, E. Brogi, V. E. Reuter, D. S. Klimstra, T. J. Fuchs, Clinical-grade computational pathology using weakly supervised deep learning on whole slide images, *Nature Medicine* 25 (2019) 1301–1309.
- [24] B. E. Bejnordi, M. Veta, P. J. van Diest, B. van Ginneken, N. Karssemeijer, G. Litjens, J. A. W. M. van der Laak, M. Hermsen, Q. F. Manson, M. Balkenhol, O. Geessink, N. Stathonikos, M. C. van Dijk, P. Bult, F. Beca, A. H. Beck, D. Wang, A. Khosla, R. Gargeya, H. Irshad, A. Zhong, Q. Dou, Q. Li, H. Chen, H.-J. Lin, P.-A. Heng, C. Hass, E. Bruni, Q. Wong, U. Halici, M. U. Oner, R. Cetin-Atalay, M. Berseth, V. Khvatkov, A. Vylegzhanin, O. Kraus, M. Shaban, N. Rajpoot, R. Awan, K. Sirinukunwattana, T. Qaiser, Y.-W. Tsang, D. Tellez, J. Annuschein, P. Hufnagl, M. Valkonen, K. Kartasalo, L. Latonen, P. Ruusuvoori, K. Liimatainen, S. Albarqouni, B. Mungal, A. George, S. Demirci, N. Navab, S. Watanabe, S. Seno, Y. Takenaka, H. Matsuda, H. A. Phoulady, V. Kovalev, A. Kalinovsky, V. Liauchuk, G. Bueno, M. M. Fernandez-Carrobles, I. Serrano, O. Deniz, D. Racoceanu, R. Venancio, Diagnostic assessment of deep learning algorithms for detection of lymph node metastases in women with breast cancer, *JAMA* 318 (22) (2018) 2199–2210.
- [25] P. Bandi, O. Geessink, Q. Manson, M. van Dijk, M. Balkenhol, M. Hermsen, B. E. Bejnordi, B. Lee, K. Paeng, A. Zhong, Q. Li, F. G. Zanjani, S. Zinger, K. Fukuta, D. Komura, V. Ovtcharov, S. Cheng, S. Zeng, J. Thagaard, A. B. Dahl, H. Lin, H. Chen, L. Jacobsson, M. Hedlund, M. Cetin, E. Halici, H. Jackson, R. Chen, F. Both, J. Franke, H. Kusters-Vandeveld,

- W. Vreuls, P. Bult, B. van Ginneken, J. van der Laak, G. Litjens, From detection of individual metastases to classification of lymph node status at the patient level: the camelyon17 challenge, *IEEE Transactions on Medical Imaging* 28 (2) (2019) 550–560.
- [26] D. Wang, A. Khosla, R. Gargeya, H. Irshad, A. H. Beck, Deep learning for identifying metastatic breast cancer, arXiv preprint arXiv:1606.05718.
- [27] Y. Liu, K. Gadepalli, M. Norouzi, G. E. Dahl, T. Kohlberger, A. Boyko, S. Venugopalan, A. Timofeev, P. Q. Nelson, G. S. Corrado, J. D. Hipp, L. Peng, M. C. Stumpe, Detecting cancer metastases on gigapixel pathology images, arXiv preprint arXiv:1703.02442.
- [28] B. Lee, K. Paeng, A robust and effective approach towards accurate metastasis detection and pN-stage classification in breast cancer, *Proceedings of the International Conference on Medical Image Computing and Computer-Assisted Intervention* (2018) 841–850.
- [29] M. Kohl, C. Walz, F. Ludwig, S. Braunewell, M. Baust, Assessment of breast cancer histology using densely connected convolutional networks, *Proceedings of the International Conference Image Analysis and Recognition* (2018) 903–913.
- [30] I. Kone, L. Boulmane, Hierarchical ResNeXt models for breast cancer histology image classification, *Proceedings of the International Conference Image Analysis and Recognition* (2018) 796–803.
- [31] L. Hou, D. Samaras, T. M. Kurc, Y. Gao, J. E. Davis, J. H. Saltz, Patch-based convolutional neural network for whole slide tissue image classification, *Proceedings of the IEEE Conference on Computer Vision and Pattern Recognition* (2016) 2424–2433.
- [32] N. Otsu, A threshold selection method from gray-level histograms, *IEEE Transactions on Systems, Man, and Cybernetics* 9 (1) (1979) 62–66.

- [33] S. Mehta, E. Mercan, J. Bartlett, D. Weaver, J. Elmore, L. Shapiro, Learning to segment breast biopsy whole slide images, Proceedings of the IEEE Winter Conference on Applications of Computer Vision (2018) 663–672.
- [34] A. Agarwalla, M. Shaban, N. M. Rajpoot, Representation-aggregation networks for segmentation of multi-gigapixel histology images, arXiv preprint arXiv:1707.08814.
- [35] M. Shaban, R. Awan, M. M. Fraz, A. Azam, D. Snead, N. M. Rajpoot, Context-aware convolutional neural network for grading of colorectal cancer histology images, arXiv preprint arXiv:1907.09478.
- [36] S. E. A. Raza, L. Cheung, D. Epstein, S. Pelengaris, M. Khan, N. M. Rajpoot, MIMO-Net: A multi-input multi-output convolutional neural network for cell segmentation in fluorescence microscopy images, Proceedings of the IEEE International Symposium on Biomedical Imaging (2017) 337–340.
- [37] S. Graham, N. M. Rajpoot, SAMS-NET: Stain-aware multi-scale network for instance-based nuclei segmentation in histology images, Proceedings of the IEEE International Symposium on Biomedical Imaging (2018) 590–594.
- [38] F. Gu, N. Burlutskiy, M. Andersson, L. K. Wilen, Multi-resolution networks for semantic segmentation in whole slide images, Proceedings of the Computational Pathology and Ophthalmic Medical Image Analysis at the International Conference on Medical Image Computing and Computer-Assisted Intervention (2018) 11–18.
- [39] H. Tokunaga, Y. Teramoto, A. Yoshizawa, R. Bise, Adaptive weighting multi-field-of-view cnn for semantic segmentation in pathology, Proceedings of the IEEE Conference on Computer Vision and Pattern Recognition (2019) 12597–12606.
- [40] J. M. Bokhorst, H. Pinckaers, P. van Zwam, I. Nagtegaal, J. van der Laak, F. Ciompi, Learning from sparsely annotated data for semantic segmenta-

tion in histopathology images, Proceedings of the International Conference on Medical Imaging with Deep Learning (2019) 84–91.

- [41] C. Fu, D. J. Ho, S. Han, P. Salama, K. W. Dunn, E. J. Delp, Nuclei segmentation of fluorescence microscopy images using convolutional neural networks, Proceedings of the IEEE International Symposium on Biomedical Imaging (2017) 704–708.
- [42] A. Paszke, S. Gross, S. Chintala, G. Chanan, E. Yang, Z. DeVito, Z. Lin, A. Desmaison, L. Antiga, A. Lerer, Automatic differentiation in PyTorch, Proceedings of the Autodiff Workshop at Neural Information Processing Systems (2017) 1–4.
- [43] M. Buda, A. Maki, M. A. Mazurowski, A systematic study of the class imbalance problem in convolutional neural networks, Neural Networks 106 (2018) 249–259.