

Anatomical Feature-guided Volumetric Registration of Multimodal Prostate MRI

Xin Zhao and Arie Kaufman

Computer science department

Stony Brook University

Stony Brook, USA

xinzhao@cs.stonybrook.edu ari@cs.stonybrook.edu

Abstract—Radiological imaging of prostate is becoming more popular among researchers and clinicians in searching for diseases, primarily cancer. Scans might be acquired at different times, with patient movement between scans, or with different equipment, resulting in multiple datasets that need to be registered. For this issue, we introduce a registration method using anatomical feature-guided mutual information. Prostate scans of the same patient taken in three different orientations are first aligned for the accurate detection of anatomical features in 3D. Then, our pipeline allows for multiple modalities registration through the use of anatomical features, such as the interior urethra of prostate and gland utricle, in a bijective way. The novelty of this approach is the application of anatomical features as the pre-specified corresponding landmarks for prostate registration. We evaluate the registration results through both artificial and clinical datasets. Registration accuracy is evaluated by performing statistical analysis of local intensity differences or spatial differences of anatomical landmarks between various MR datasets. Evaluation results demonstrate that our method statistics-significantly improves the quality of registration. Although this strategy is tested for MRI-guided brachytherapy, the preliminary results from these experiments suggest that it can be also applied to other settings such as transrectal ultrasound-guided or CT-guided therapy, where the integration of preoperative MRI may have a significant impact upon treatment planning and guidance.

Keywords- *Anatomical feature; MI registration; Multimodal prostate MRI*

I. INTRODUCTION

Prostate cancer is the second leading cause of cancer-related mortality among males in the United States, and is the most commonly diagnosed cancer in general [9]. Although it is such a common cancer, diagnosis methods remain primitive and inexact. More recently, Magnetic Resonance Imaging (MRI) has been used for the detection of prostate cancer. MRI provides superior soft-tissue contrast and visualization of tumor invasion of surrounding soft tissues. Moreover, MRI provides images in nonaxial planes (sagittal and coronal), thus allowing better 3D representation of the tumor volume. Standard MR imaging can clearly define the prostate and its sub-structures, as well as the rectum, neurovascular bundles and urethra. Further, several new MR imaging methods have recently shown promise in their ability to detect and characterize

prostate cancer. These include MRSI (spectroscopy), diffusion imaging, and MR imaging with dynamic intravenous contrast enhancement. In this paper, we use a combination of T2-weighted MR and MRSI image sequences. T2-weighted MR images are generally of high quality and resolution, while prostate cancer can be accurately detected by MRSI. The acquisition of these MR image sequences is often done with varying orientations and resolutions per sequence. The prostate, being composed of soft tissues, can undergo significant shape changes between different imaging sessions by the procedures [4]. Therefore, registration methods are necessary for multiple MR sequences for different positions or time periods. Meanwhile, it is possible that doctors might want to correlate MR images to histology information in order to confirm results during development and testing of a system. In this paper, we propose a novel volumetric registration framework, which can help register various MR datasets and reduce the work of radiologists, to monitor the progression of abnormalities, and to facilitate the diagnoses of prostate diseases. The pipeline consists of the anatomical feature detection, alignment, and registration. We first detect the anatomical features of each prostate dataset as landmarks. Then we use specified feature points to align and register two different prostate datasets. Finally, we evaluate our registration results using statistical analysis based on the differences of local intensity or landmark position of prostates.

This paper is organized as follows. In Section 2 we review the previous work on prostate registration methods. Then we introduce our design and algorithm in Section 3. Experimental results and evaluations are shown in Section 4. We conclude our discussion and sketch the future research plan in Section 5.

II. RELATED WORK

Registration of multimodal prostate images is important for the planning, guidance, and retrospective evaluation of radiotherapy procedures; and the fusion of diagnostic images for improved CaP detection accuracy. Intra-modality prostate image registration has been utilized by Bharatha et al. [1] for image-guided prostate surgery via elastic registration of preoperative and intraoperative prostate MRI. Lee et al. [6] have investigated the use of multimodal prostate images (MRI, CT, and SPECT) to characterize CaP, performing automated

multimodal registration of MRI to SPECT via manual registration of MRI to CT using a graphical user interface. Manually identified control points (anatomical landmarks), placed primarily along the gland boundary, are used to define a thin plate spline interpolation. Automated rigid registration of MRI to CT has been addressed by several groups [13]. Park et al. [7] have addressed an automated elastic registration using a spatially constrained B-spline. For the close feature visualization and detection, Zhao et al. [19] have provided a context preservation visualization style and further extend it into 4D [15]. For registration of MRI to histology information, Zhan et al. [14] have first applied anatomical structures as landmarks for the prostate data. However, their anatomical structures vary in different patient cases and the feature detection is extremely time-consuming. By comparison, our method has automatic performance by the application of develop a registration framework using anatomical feature-guided mutual information to automatically map spatial extent of corresponding MRI datasets; and (2) our method improves over intensity-based similarity metrics by incorporating unique feature landmarks that are relatively robust and accurate to accentuate structural details in the target and template images to be registered. Our framework allows for the incorporation of multiple modalities, protocols, or even features images in an automated registration scheme, facilitated by the use of MI. Additionally, the application of MI involves a simple optimization procedure without any pre-segmentation.

III. DESIGN METHODS

In this section, we focus on the feature detection, and the design of feature-guided registration of prostate MR datasets.

A. Anatomical Feature Detection of Prostate

The prostate gland, which surrounds the urethra, is located in front of the rectum, and just below the bladder. Within the prostate, the urethra coming from the bladder is called the prostatic urethra and merges with the two ejaculatory ducts. MRI provides images with excellent anatomical detail and soft-tissue contrast. We analyze T2-weighted datasets along the axial, sagittal and coronal view in 3D, as shown in Figure 1(a). The seminal vesicles are tucked between the rectum and the bladder, and attached to the prostate. The urethra goes through entire prostate and joins with two seminal vesicles at the ejaculatory ducts. Therefore, some distinctive anatomical structures, such as ejaculatory ducts, urethra, and dilated gland with prostatic utricle, as represented in Figures 1(b) and (c), can be applied for the registration between different scan directions or between MRI slices and MRSI sequences. On each MRI or MRSI prostate view direction, all corresponding feature points can manually marked with predefined index numbers through the user interface, which can be considered as ground truth references for the automatic feature detection (e.g., a corresponding urethral feature point is marked in three view directions, as shown in Figure 2).

consistent feature points for registration of various MRI and MRSI datasets.

Multi-protocol MR imaging is part of standard clinical practice at a number of medical centers for disease diagnosis and treatment [5]. Traditional intensity-based similarity measures, such as mutual information (MI), are typically inadequate to robustly and automatically register images from these significantly dissimilar modalities. There have been several efforts to complement intensity information with alternative image information, including image gradients [8] and image segmentations [11] in conjunction with MI variants, specifically adapted to incorporate these additional channels of information. Inspired by the application of additional image information, our paper has the following contributions: (1) we

Automatic anatomical feature detection. In order to effectively process a large number of datasets, several automatic feature detection methods are embedded into our framework. Corner detection or the more general terminology interest point detection is an approach used within computer vision systems to extract certain kinds of features of an image. We apply the fast corner and blobs detection method [10] to automatically recognize the urethra utricle points as the identified interior feature points on the axial MR images. Several false positive feature points may be detected by this algorithm, but our system allows the user to interactively mark and highlight accurate anatomical features, and delete the false positive points. We also apply the Hough transform [2] for the detection of entire urethra on the sagittal MR images. The Hough transform can find instances of objects within a certain class of shapes by a voting procedure in a parameter space, but will generate some false positive line segments. In order to solve this problem, Grey-Level Co-occurrence Matrices (GLCM) defined in [3] as local texture features are further used to refine the urethra detection based on the pre-defined reference texture (manually marked by the user). Figure 3 shows the automatic feature detection results on MR images.

B. Anatomical Feature-guided Registration

For volumetric alignment, we need to match three identical interior anatomical features (major features in the prostatic utricle shown in Figure 1b) within the MR images of different datasets or modalities to obtain accurate and reliable registration results. For volumetric registration, we apply a commonly used similarity measure as the mutual information [12], due to the robustness of the MI measure to differences in intensity patterns between image modalities and protocols. Our design provides a more effective approach to exploit all the information acquired from prior alignment steps to drive the subsequent registration operations, which is fast and accurate.

IV. EXPERIMENTAL RESULTS AND EVALUATION

In this section, we register different prostate MR datasets and modalities using both intensity information and anatomical

feature points. Then, we evaluate our design using artificially deformed and clinical MR datasets.

Artificial deformation datasets. We firstly evaluate the registration algorithm by artificially deforming a dataset by a linear transformation, and then register back to itself. The linear deformation approximation is well-deformed, and the image intensities of the deformed volume are interpolated from the original dataset, which provides an accurate estimation. Therefore, with the known ground truth, the mean squared difference (MSD) between the registered voxels could directly give us a good understanding of the performance of our anatomical feature based registration method. We apply our framework to 5 T2-weighted MR cases. The MSD of intensity values between the registered volume and the original volume using or without using the anatomical feature based landmarks, is calculated for each deformation case. Figure 4 shows the average prostate boundary (manually drawn after registration for each test case) and the voxel-wise MSD of intensity for all the test cases.

Clinical MRI datasets. In cases where considerable image differences between modalities (e.g. MRI and histology) exist, and when imaging artifacts (e.g. bias field inhomogeneity in MRI) are present, traditional intensity difference measurement is inadequate and inaccurate. Therefore, the MSD of voxel intensity may not be a good criterion for evaluation in the multimodal situation. We notice that identical feature points are consistent in world coordinate space, which inspires us to use the voxel-wise difference of their world coordinates as the criterion. In fact, if the volumes are registered, the differences of world coordinates have a correlation among voxels. Thus, we can use both interior and exterior (surface) feature points as landmarks to compare the spatial distance differences between registered multimodal datasets without and with anatomical features. Three exterior feature points are detected and marked based on the structure information of prostatic urethra and seminal vesicles: two surface feature points exactly located at the entrance and exit points of the urethra are manually picked. The third surface point is manually marked at the intersection between one seminal vesicle and the prostate gland with respect to the fact that seminal vesicles attach to the surface of prostate and merge with the urethra at the ejaculatory ducts. A set of interior feature points are marked along the urethra following the user defined criteria (e.g., equidistant sampling), beginning with the entrance surface feature point and ending with the exit one.

We test our method using 5 cases of two modalities: T2-weighted MRI and MRSI. Figure 5 shows the voxel-wise spatial differences of all the anatomical feature based landmarks between two modalities of a test case in the world coordinates without or with interior anatomical features as alignment for registration.

Statistical analysis. The statistical analysis is performed using the SPSS software (version 10.0). One-way ANOVA

(Analysis of Variance) is used to analyze the difference between MI registration without and with anatomical features as landmarks. A twotailed p value of $p < 0.05$ is considered statistically significant in all cases. All the cases in both situations (artificial and clinical datasets) show the statistically significant improvement by the use of anatomical features for prostate registration.

V. CONCLUSIONS AND FUTURE WORK

In this paper, we perform a registration of volumetric MRI prostate using anatomical feature-guided mutual information. Analysis and evaluation, using the differences of local intensity and Euclidean distance of anatomical feature points as metrics for the statistical analysis, show that our anatomical feature-guided MI registration framework has a significant improvement over the registered results without using feature-guided landmarks. Our framework is able to provide the physician with an integrated view of the intra-operative and high quality pre-operative imaging during the biopsy procedure. Although presented here for MR imaging, our pipeline has further potential applicability to other less discriminating but widely used intra-operative imaging modalities such as CT and ultrasound, since the method is affected by different scanning protocols for the target gland. We plan to test our framework for these modalities in the future. In addition, potential uses of our method include the registration of other organs, and applications such as the creation of models of organ variability using principle component analysis. Moreover, inspired by the methods proposed in [16, 17, 18], the volumetric feature detection algorithm can further increase the detection accuracy.

ACKNOWLEDGMENT

This paper has been supported by NSF grants IIS0916235, CCF0702699 and CNS0959979 and NIH grant R01EB7530.

REFERENCES

- [1] A. Bharatha, M. Hirose, N. Hata, S. Warfield, M. Ferrant, K. Zou, E. Suarez-Santana, J. RuizAlzola, A. D'Amico, R. Cormack, R. Kikinis, F. Jolesz, and C. Tempny. Evaluation of three-dimensional finite element-based deformable registration of pre- and intra-operative prostate imaging. *Medical Physics*, 28:2551–2560, Dec. 2001.
- [2] R. O. Duda and P. E. Hart. Use of the hough transformation to detect lines and curves in pictures. *Comm. ACM*, 15:11–15, 1972.
- [3] R. Haralick, K. Shanmugam, and I. Dinstein. Textural features for image classification. *IEEE Transaction on Systems, Man, and Cybernetics*, pages 269–285, 1973.
- [4] M. Hirose, A. Bharatha, N. Hata, K. Zou, S. Warfield, R. Cormack, A. DiAmico, R. Kikinis, F. Jolesz, and C. Tempny. Quantitative MR imaging assessment of prostate gland deformation before and during MR imaging-guided brachytherapy. *Acad. Rad.*, 9(8):906–912, 2002.
- [5] J. Kurhanewicz, M. G. Swanson, S. J. Nelson, and D. B. Vigneron. Combined magnetic resonance imaging and spectroscopic imaging approach to molecular imaging of prostate cancer. *J. Magn. Reson. Imaging*, 16:451–463, 2002.
- [6] Z. Lee, D. B. Sodee, M. Resnick, and G. T. MacLennan. Multimodal and 3D imaging of prostate cancer. *Comput. Med. Imaging Graph.*, 29:477–486, 2005.

- [7] S. B. Park, F. C. Rhee, J. I. Monroe, and J. W. Sohn. Spatially weighted mutual information image registration for image guided radiation therapy. *Med. Phys.*, 37:4590–4601, 2010.
- [8] J. Pluim, J. Maintz, and M. A. Viergever. Image registration by maximization of combined mutual information and gradient information. *IEEE Trans. Med. Imaging*, pages 809–814, 2000.
- [9] L. A. G. Ries, D. Melbert, M. Krapcho, D. G. Stinchcomb, N. Howlader, M. J. Horner, A. Mariotto, B. A. Miller, E. J. Feuer, S. F. Altekruse, D. R. Leis, L. Clegg, M. P. Eisner, M. Reichman, and B. K. Edwards. SEER cancer statistics review, the national cancer institute. http://seer.cancer.gov/csr/1975_2005/.
- [10] E. Rosten, R. Porter, and T. Drummond. Faster and better: A machine learning approach to corner detection. *IEEE Transactions on Pattern Analysis and Machine Intelligence*, 32(1):105–119, 2010.
- [11] C. Studholme, D. Hill, and D. J. Hawkes. Incorporating connected region labeling into automatic image registration using mutual information. *Mathematical Methods in Biomedical Image Analysis*, 3979:23–31, 1996.
- [12] P. Thevenaz and M. Unser. Optimization of mutual information for multiresolution image registration. *IEEE Transactions on Image Processing*, 9(12):2088–2099, 2000.
- [13] S. Vidakovic, H. S. Jans, A. Alexander, and R. S. Sloboda. Post-implant computed tomography/magnetic resonance prostate image registration using feature line parallelization and normalized mutual information. *J. Appl. Clin. Med. Phys.*, 8(1):21–32, 2007.
- [14] Y. Zhan, Y. Ou, M. Feldman, J. Tomaszewski, C. Davatzikos, and D. Shen. Registering histologic and MR images of prostate for image-based cancer detection. *Academic Radiology*, 14(11):1367–1381, 20
- [15] Bo Li, Xin Zhao, and Hong Qin. Four Dimensional Geometry Lens: A Novel Volumetric Magnification Approach. *Computer Graphics Forum* (pre-print)
- [16] Bo Li, Xin Li, Kexiang Wang, and Hong Qin. Surface Mesh to Volumetric Spline Conversion with Generalized Polycube. *IEEE Transactions on Visualization and Computer Graphics*, in press.
- [17] Bo Li, and Hong Qin. Component-aware Tensor-product Trivariate Splines of Arbitrary Topology. *Computer & Graphics*, 36(5): 329–340, 2012.
- [18] Kexiang Wang, Xin Li, Bo Li, and Hong Qin. Restricted Trivariate Polycube Splines for Volumetric Data Modeling. *IEEE Transactions on Visualization and Computer Graphics*, 18(5): 703–716, 2012.
- [19] Xin Zhao, Bo Li, Lei Wang, and Arie Kaufman. Texture-guided Volumetric Deformation and Visualization Using 3D Moving Least Squares. *The Visual Computer*, 28(2): 193–204, 2012

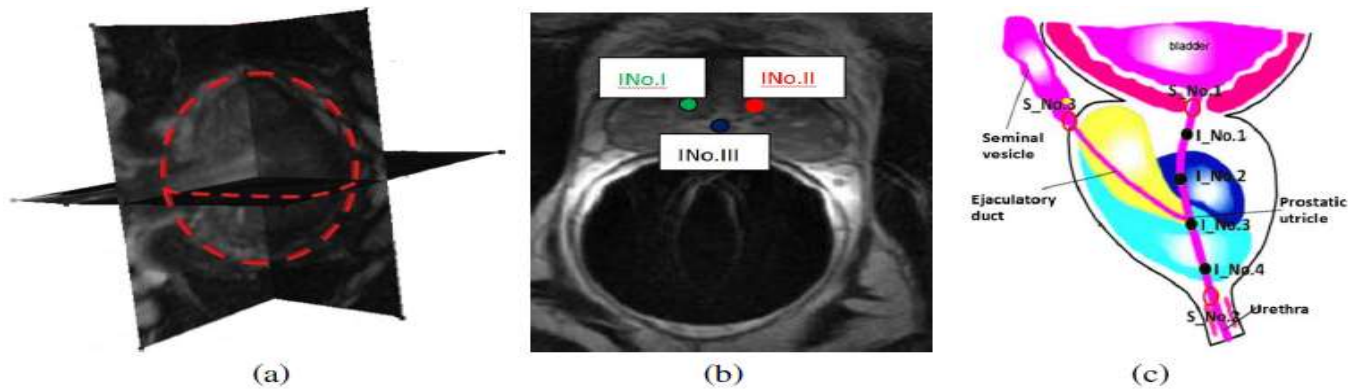


Figure 1. Anatomical feature points of prostate. (a) Multi-view of prostate MR images along three view directions. (b) An axis slice shows the identified interior anatomical feature points (prostatic utricle) used for the alignment. (c) The illustration of anatomical feature points as landmarks used for the evaluation. Each feature point is marked with a pre-defined index number. S Nos are the surface feature points, while I Nos are the interior feature points.

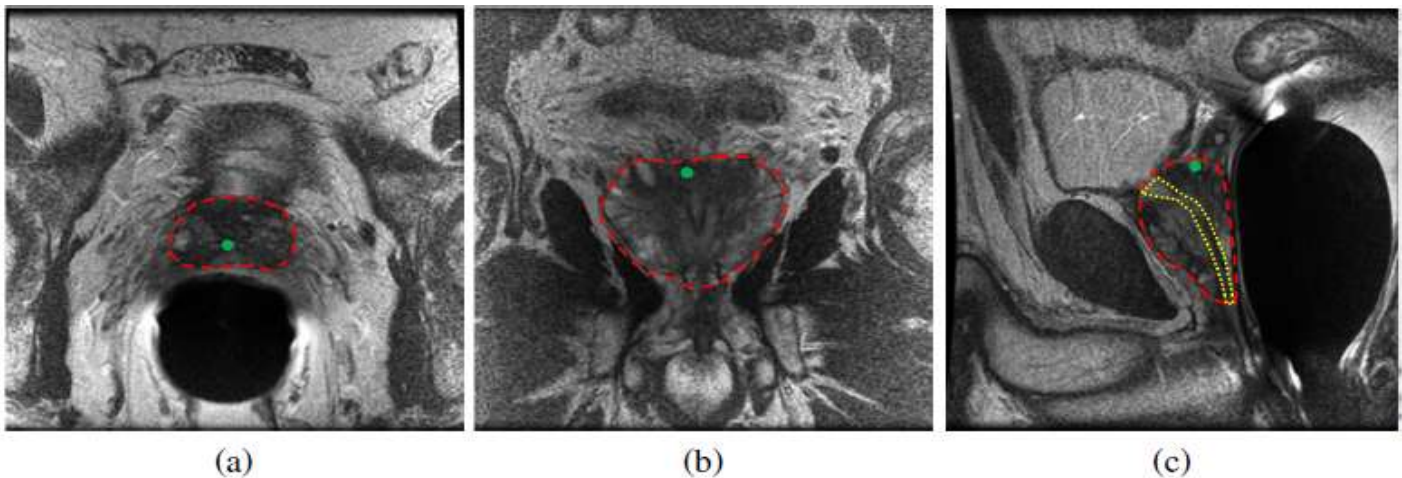


Figure 2. Results of our automatic feature detection design for (a) the axis and (b) the sagittal MR images. The small images highlighted by yellow frames show detected features (red points or line) in the prostate region.

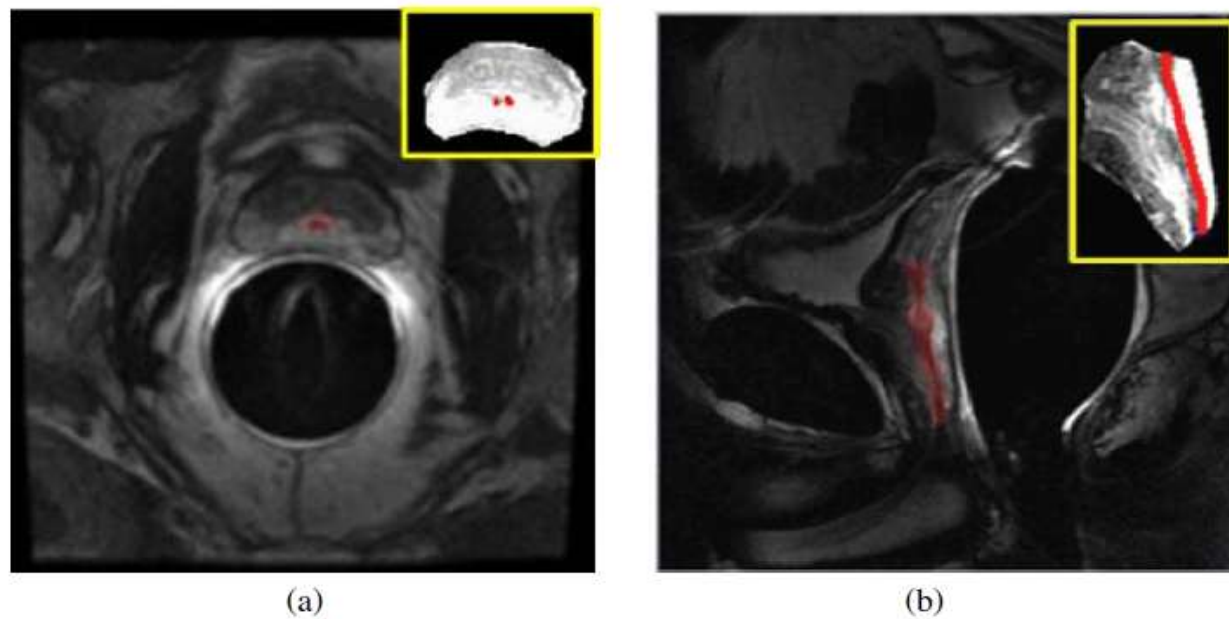


Figure 3. Results of our automatic feature detection design for (a) the axis and (b) the sagittal MR images. The small images highlighted by yellow frames show detected features (red points or line) in the prostate region.

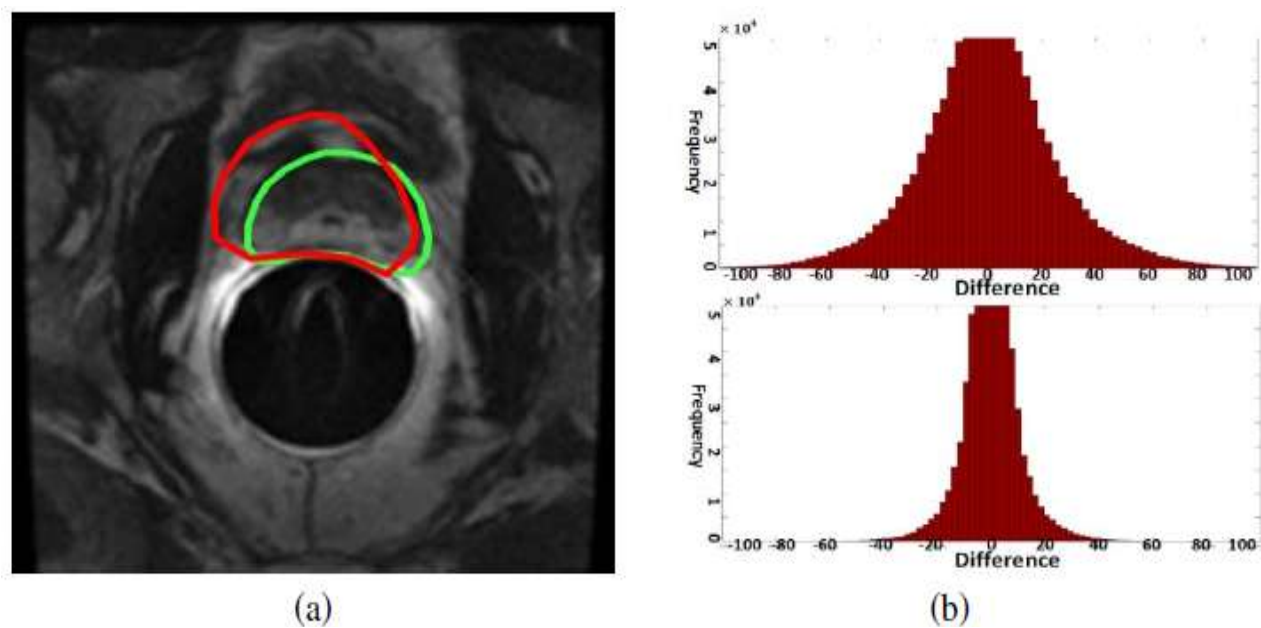


Figure 4. Registration results of artificial deformation $ST_{[2]}$ -weighted MR datasets. (a) The average prostate boundary detected without using anatomical feature points (red curve), and using anatomical feature points (green curve). The result shows that our framework is able to register various datasets consistently and accurately. (b) The MSD of image intensity values without using anatomical feature points (top), and using anatomical feature points (bottom). Histograms show that differences are much smaller using our feature-guided framework for registration.

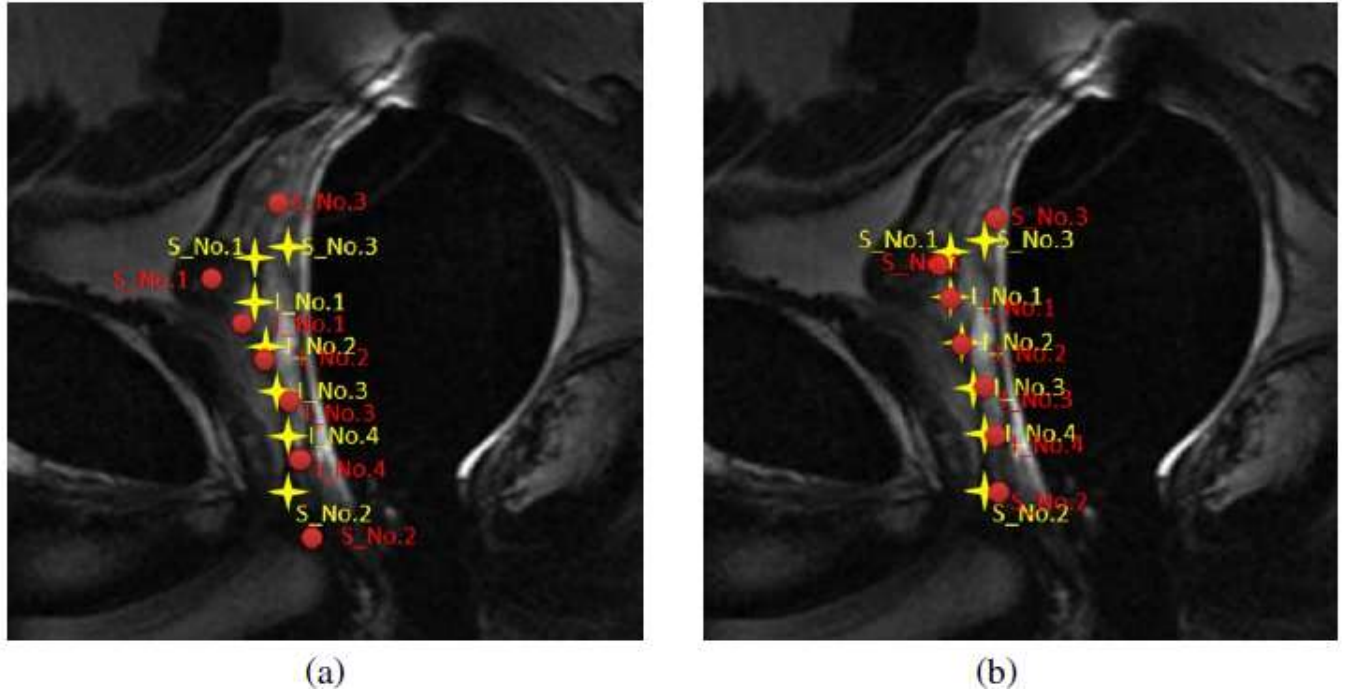


Figure 5. The voxel-wise spatial distance differences of each corresponding landmark pair (a) without using anatomical feature points, and (b) using anatomical feature points for multimodal registration. Feature points are detected from T2-weighted MRI (yellow) and MRSI (red). Experimental results show that the spatial distance difference of each landmark is much smaller using our feature-guided framework for multimodal prostate registration